We will now show how the findings of Todd and D'Errico compare with our own.

3. Medial Epiphysis

Table 28 summarizes the data according to side. At first glance there seems to be some difference in the progress of union between the right and left sides, but these differences occur only in the early age groups and are not large enough to be significant. For example, in the 18 year age group, union in the right clavicle does not exceed stage 1, whereas in the left it has reached stage 2 in 2 percent of the cases. Irregularities of this kind can be seen in the age groups from 18 to 23, after which differences between the right and left sides are absent. Of course, it is easy to displace epiphyseal caps in these early ages and, therefore, differences between sides may arise simply from the loss of one of the caps.

TABLE 28

AGE DISTRIBUTION OF THE STAGES OF UNION
FOR THE MEDIAL CLAVICULAR EPIPHYSIS
(in %)

		Right					Left				
		Stage of Union					Stage of Union				
Age	No.	0	1	2	3	4	0	1	2	3	4
17	10	-	-	-	-	-	-	-	-	-	-
18	45	90	10	-	-	-	86	12	2	-	-
19	52	79	13	8	-	-	73	21	4	-	-
20	45	69	28	11	2	-	56	35	7	2	-
21	37	36	43	13	8	-	47	32	13	8	-
22	24	4	27	39	30	-	1	33	37	29	-
23	26	-	11	43	40	6	-	8	43	40	9
24-25	27	-	3	10	52	37	-	3	10	52	37
26-27	25	-	-	-	36	64	-	-	-	36	64
28-29	18	-	-	-	31	69	-	-	-	31	69
30	11	-	-	-	9	91	-	-	-	9	91
31	54	-	-	-	-	100	-	-	-	-	100
Total	374										

Although beginning union appears first at 18 years in our series, we cannot be sure that this stage does not occasionally appear at 17 years since 10 cases constitute an inadequate sample for this age.

Clavicles with unattached epiphyses may be found as late as 22 years. On the other hand, it is interesting to note that cases of completed union do not appear before the age of 23 years.

Variability of union, as expressed in Table 28 by the distribution of the stages over as many as 6 to 8 age groups, makes it impossible to associate particular ages with stages of union. Only a probable age for beginning union (17 years) and a definite age for the last stage of union (30 years) can be given.

The results do not agree with those of Todd and D'Errico, yet upon closer inspection, the disagreement seems to reflect mainly difference in interpretation. This is shown in a further comparison of the two series (Tables 29 and 30) involving percentages of occurrence for beginning and complete stages of union in selected age groups. For this purpose we have judged beginning union, as recorded by Todd and D'Errico, to be equivalent to our stages 1 and 2, and their complete union to our stage 4.

TABLE 29

THE OCCURRENCE OF BEGINNING EPIPHYSEAL UNION: COMPARISON BETWEEN THE TODD AND D'ERRICO SERIES AND THE AMERICAN WAR DEAD SERIES.

	Todd and D'Errico Series*		American War Dead Series	
Age	No.	%	No.	%
17	2	-	10	-
18	8	-	45	10
19	4	-	52	21
20	12	8	45	39
21	12	58	37	56
22	11	81	24	66
23	14	64	26	54
Total	63		237	

*Whites and Negroes combined (after Todd and D'Errico, 1928, p. 37-38).

In Table 29 the Todd and D'Errico series does not reveal beginning union before the 20th year, the samples representing the preceding years being too small to reveal significant trends. Our data show beginning union as early as 18 years. Yet Todd and D'Errico claim that the sternal epiphysis commences to unite about the 21st and 22nd year (p.49). Obviously, therefore, they are talking about the age when over 50 percent of

the cases are in this stage. This is misleading for identification purposes.

Todd and D'Errico also state that complete union does not take place until the 25th year (p. 49). Actually, Table 30 shows that complete union first appears in their series at age 23, just as in ours. However, partial substantiation of their conclusion is exhibited by the abrupt decrease of epiphyseal activity after 25 years. This change is further emphasized in Table 30 where the percentages in Todd's series show a dramatic increase from little or no occurrence of complete union, in ages 24 and 25 respectively, to 36 percent in age 26. In other words, the differences between the two series are not great and could easily derive from the small numbers in each age group. It can be generally stated, therefore, that from the age of 26 to 30, last stages of union are found in only a few cases and complete union occurs in the majority of cases around the age of 25.

TABLE 30

THE OCCURRENCE OF COMPLETE EPIPHYSEAL UNION: COMPARISON BETWEEN THE TODD AND D'ERRICO SERIES AND THE AMERICAN WAR DEAD SERIES.

	Todd and D'Errico Series*		American War Dead Series	
Age	No.	%	No.	%
22	11	-	24	-
23	14	7	26	6
24	14	7	14	21
25	9	-	13	61
26	12	36	15	60
27	12	25	10	60
28	12	50	13	61
29	8	75	6	67
Total	92		121	

*Whites and Negroes combined (see footnote to Table 29).

Unlike most of the limb epiphyses which correspond in size to the surface to be covered, the medial clavicular epiphysis often is reduced in size or does not develop at all. In such cases, Todd claims, "the epiphyseal cartilage disappears and the same waxy textured bone which is typical of the epiphysis glazes over the naked end of the shaft" (p. 49). This seems to be borne out by the fact that Flecker (1942,p.110) could not see the cap of the medial epiphysis in his x-rays in more than 65 percent of the cases. Though Todd and D'Errico have described this character

in some detail and emphasized the difficulties met by the observer who must identify the two conditions, they have not revealed how often it occurred in their sample.

In the absence of epiphyseal ossification, how can the end stages of maturation be recognized? Also, can the non-development of an epiphysis lead to an erroneous age estimate? About the only way we can answer these questions is to point out that the mature appearance resulting from epiphyseal glazing alone probably develops slowly. In the absence of a cap to cover the billowed surface we cannot see how such a surface can be smoothed over quickly. This consideration leads us to conclude that under these conditions there is no clear point at which maturation can be said to be complete; cases may appear younger than they are.

Let us turn now to the photographs and casts of the medial end of the clavicle. Out of 77 cases in the age groups 22 to 25 which include the periods of late epiphyseal activity, we were able to detect only one (age 24) where the epiphysis had not developed. The cast in this case has no epiphysis, yet a portion of its superior face is glazed over in marked contrast to the billowed appearance of the remaining surface (Fig. 45). It was recorded on the data card as, "1 or 2(probably 2)" which places the cast at the extreme end of the age frequency for either of these stages (see Table 28). Thus, we can only conclude that: 1) cases of non-ossification can be recognized only in those age groups (22-25) which normally possess epiphyseal caps in late stages of union, and 2) within these age groups, the incidence of recognized cases of non-ossification is low.

Fig. 45 Left and right surfaces of the clavicle showing example of non-ossification. (No. 231, 24 years). Note glazed surface and absence of epiphysis.

Other than the above observation, epiphyseal caps showing stages of union appear in about 20 percent of the casts in our series. Of these cases, 91 percent show union beginning at the superior margin of the epiphyseal face (Fig. 46). As for the last stages of union, 96 percent of the casts demonstrate fissures at the inferior margin (Fig. 47). Union at the anterior and posterior margins is variable.

Fig. 46 Left and right medial surfaces of the clavicle showing beginning epiphyseal union at the superior margin. (No. 82, 20 years).

Fig. 47 Left and right medial surfaces of the clavicle showing late stages of epiphyseal union. (No. 111, 25 years).

One of the characteristic features of the medial end of the clavicle is its diversity in shape. Todd recognized this fact and divided his series into four types: plane, convex, concave and sigmoid (p. 30). However, on the basis of our observations, the variety of shapes seems to be far greater. For example, the outline of the epiphyseal face may be round, square, triangular or oblong, while the surface varies from deeply concave to convex. This variability tends to discourage any set classificatory procedure. For this reason and also since the shape of the medial end of the clavicle seems to have no influence on the course of the epiphyseal maturation, we feel that a few illustrations will give the reader a sufficient idea of the variability to be found in this area (Fig. 48 and 49).

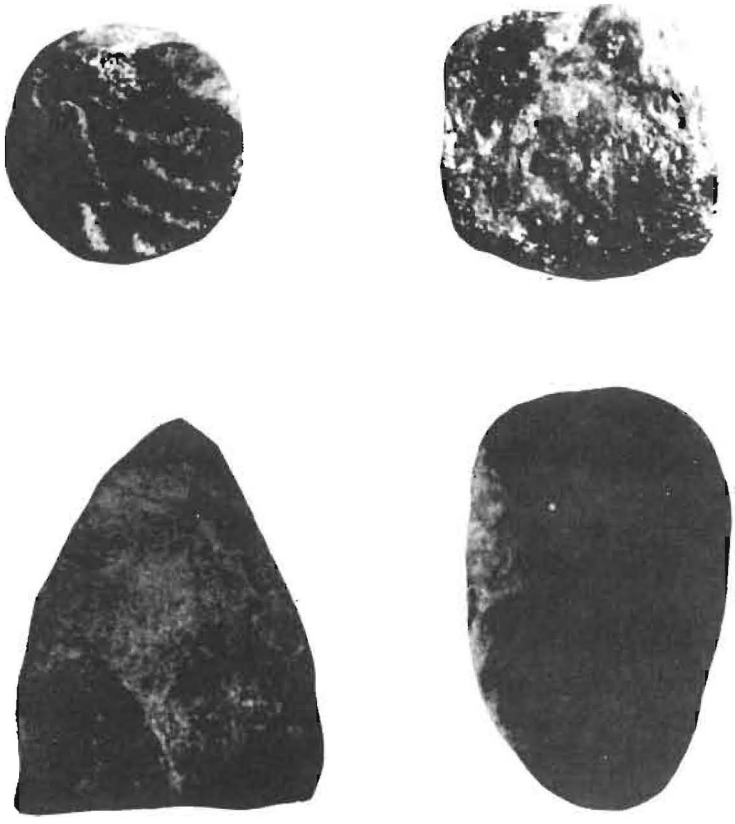

Fig. 48 Medial surfaces of the clavicle showing the variability in shape. Upper left: Round (No. 51, 18 years). Upper right: Square (No. 66, 26 years). Lower left: Triangular (No. 330, 22 years). Lower right: Oblong, (No. 108, 27 years).

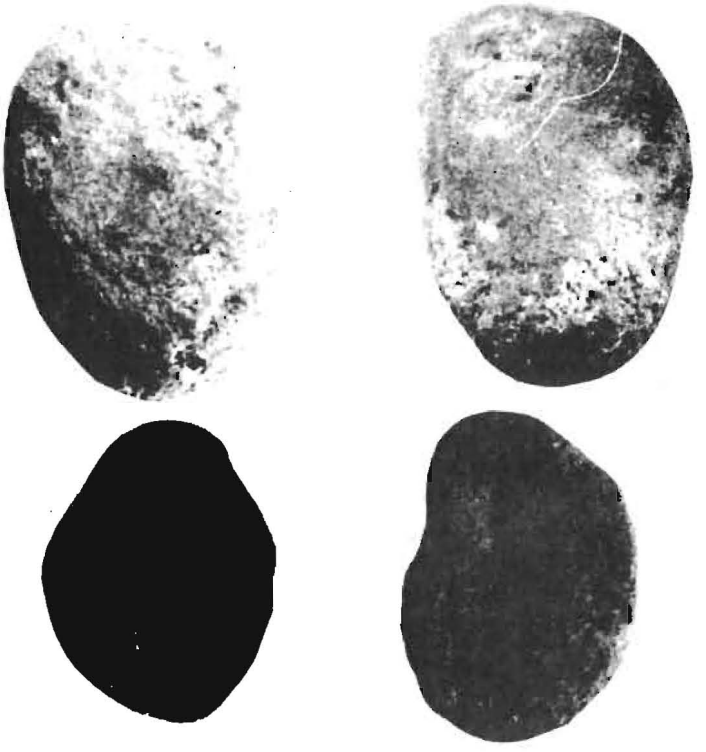

Fig. 49 Medial surfaces of the clavicle showing the variability in surface shape. Upper: Convex (No. 78, 28 years) (left and right). Lower: Deeply concave, (No. 193, 29 years) (left and right).

4. Summary

As early as 18 years but any time between 18 and 25 years, the epiphyseal cap begins to unite to the billowed surface of the medial end of the clavicle. Union begins at the approximate center of the face and spreads to the superior margin where it may progress either anteriorly or posteriorly. From 25 to 30, the majority of cases are undergoing terminal union. The last site of union is located, in the form of a fissure, along the inferior border. With the obliteration of these fissures (at age 31), the epiphysis is completely united.

CHAPTER VI

VERTEBRAL COLUMN

1. Introduction

The presacral vertebral column is composed of 23 to 26 segments which are differentiated functionally into 3 sections: cervical (7), thoracic (11-13) and lumbar (4-6). With the exception of some of the cervical vertebrae, each segment, regardless of its position in the column, presents at least 5 epiphyses: 2 for the centrum in the form of superior and inferior rings, one for the tip of each transverse process, and one for the tip of the spinous process. The progress of union of all these epiphyses is important in skeletal ageing. However, we shall limit our attention to the 2 epiphyses of the centrum (Fig. 50) and to the epiphysis of the spinous process.

Fig. 50 Anterior surface of L-1 showing unattached epiphyses of the vertebral centra. (No. 139, 18 years).

We are unable to say whether the epiphyses for the transverse processes are already united at the beginning age of our series, for no provision was made for recording them and the photographs are not distinct enough to give us the detailed information.

Age changes in the vertebral column, other than epiphyseal maturation, include lipping of the anterior borders of the centra, the appearance and disappearance of striations on the surfaces of the centra, and spur formations on the superior borders of the laminae. Observations were recorded for these features.

2. Historical Remarks

A review of the literature on the presacral vertebral column reveals a lack of exact knowledge on epiphyseal maturation. Stevenson (1924) did not include these epiphyses in his study and Flecker (1942) limited his attention to the time of their first appearance (probably because his series did not go beyond the age of 17). Anatomy textbooks usually reflect this state of affairs by stating simply that the epiphyses of the vertebrae unite in the 25th year.

TABLE 31

THE AGE DISTRIBUTION OF STAGES OF UNION FOR THE SUPERIOR AND INFERIOR EPIPHYSEAL RINGS OF THE PRESACRAL COLUMN AS A WHOLE
(in %)

		Superior Surface					Inferior Surface				
		Stages					Stages				
Age	No.	0	1	2	3	4	0	1	2	3	4
17-18	54	5	22	37	23	13	2	24	37	23	13
19	50		10	30	36	24		8	32	48	14
20	43		7	14	33	46		7	14	37	42
21	35			20	27	63			20	36	44
22	24			4	8	88			4	8	88
23	26				7	93				11	89
24-25	27					100					100
Total	259										

3. Epiphyseal Rings of the Centra

The progress of union for the epiphyses of the centra in the column as a whole is portrayed as a composite rating resulting from a general impression made while viewing the specimen. Table 31 summarizes these observations. Stages 2 and 3 appear most commonly between the ages of 19 and 21, and stage 4 is always present by 24 years. Also, there is no significant difference in the rate of union between superior or inferior

Fig. 51 Various views of the 1st lumbar vertebra showing stages of union.
Upper left: Stage 1 (No. 40, 18 years). Upper right: Stage 2 (No. 284, 18 years).
Bottom: Stage 3 (No. 11, 17 years).

rings. (See Fig. 51 illustrating stages of union).

In Table 32 we have recorded the age distribution of complete union for each of the thoracic vertebrae in order to show the local pattern of maturation. At the age of 20, complete union is seen only in the first and last 5 thoracic segments (T-1, T-8, T-9, T-10, T-11, and T-12). Thereafter, until the age of 24, there is a definite and consistant lag throughout the age groups in the region between T-2 and T-7, but especially in segments T-4 and T-5. Thus, it is important to examine these segments for the last signs of epiphyseal union in the presacral spine.

TABLE 32

AGE DISTRIBUTION OF THE COMPLETE UNION FOR THE EPIPHYSEAL RINGS OF THE INDIVIDUAL THORACIC VERTEBRAL CENTRA
(%)

		Thoracic Vertebrae											
Age	No.	1	2	3	4	5	6	7	8	9	10	11	12
17-18	54	13	13	13	8	4	4	8	13	13	13	13	13
19	50	24	22	14	6	8	8	22	24	24	24	24	24
20	43	100	86	77	70	68	77	96	100	100	100	100	100
21	35	100	92	83	86	83	89	95	100	100	100	100	100
22	24	100	96	84	67	71	91	96	100	100	100	100	100
23	26	100	97	93	81	85	97	100	100	100	100	100	100
24-25	27	100	100	100	100	100	100	100	100	100	100	100	100
Total	259												

4. Vertebral Spines

Because the spinous processes were often damaged, thus making doubtful the status of epiphyseal union there, detailed observations were not attempted. However, on the basis of what could be seen, Table 33 shows that maturation for the epiphyses of the spinous processes parallels that for the epiphyseal rings of the centra. Active union occurs between the ages of 19 and 21 while union is completed in all cases by 24 years of age.

TABLE 33

AGE DISTRIBUTION OF STAGES OF UNION FOR THE EPIPHYSES OF THE VERTEBRAL SPINES (in %)

Age	No.	Stages 0	1	2	3	4
17-18	52	21	16	20	18	25
19	51	7	10	15	27	41
20	42	4	3	7	14	72
21	34			11	12	77
22	23				4	96
23	26				3	97
24-25	27					100
Total	255					

5. Vertebral Striations

The immature surfaces of the vertebral centra have an appearance which recalls the billowed epiphyseal surfaces elsewhere in the skeleton, and especially the symphyseal faces of the pubis. In the centra, the billowing takes the form of striations, which radiate from the center of the surface out toward the borders. These striations disappear in time and the surface becomes irregular and pitted (Fig. 52).

Table 34 shows the occurrence of striations on the thoracic and lumbar centra for ages 22 to 50 and thus demonstrates the areas of concentration as well as their rate of disappearance. As is seen, striations are highly variable and are confined to the lumbar and low thoracic centra. They occur in about 30 percent of the lumbar centra in the middle twenties and persist only in low percentages in the age groups beyond 31 years. Although striations were observed in the 41-50 age group, we feel that exact age at which striations finally disappear cannot be stated.

The persistence of vertebral striations into the fifth decade denies their utility for purposes of age identification. They constitute an additional feature supporting age determinations derived from the symphyseal surface of the pubis.

Fig. 52 Superior surfaces of first lumbar vertebrae showing: Left: billowed striations (No. 44, 18 years). Right: older surface minus striations but irregular and pitted (No. 360, 32 years).

TABLE 34

AGE DISTRIBUTION DEMONSTRATING THE OCCURRENCE OF STRIATIONS ON THE SURFACE OF THE VERTEBRAL CENTRA
(in %)

		Thoracic												Lumbar				
Age	No.	1	2	3	4	5	6	7	8	9	10	11	12	1	2	3	4	5
22	25												16	28	32	32	32	32
23	26										4	8	15	30	30	30	30	30
24-25	26												15	30	30	30	30	30
26-27	25											5	20	28	20	16	16	16
28-30	29												6	20	13	13	13	13
31-40	43											2	11	11	8	8	8	8
41-50	6													-	-	-	-	-
Total	162																	

6. Vertebral Lipping

As seen in Table 35, the degree of lipping in the present series is mostly limited to stage 1. However, this stage increases in frequency

TABLE 35

AGE DISTRIBUTION FOR STAGES OF VERTEBRAL LIPPING FOR THE PRESACRAL COLUMN AS A WHOLE.
(in %)

		Stages				
Age	No.	0	1	2	3	4
17-18	55	93	7			
19	52	96	4			
20	43	95	5			
21	37	95	5			
22	25	92	8			
23	26	89	11			
24-25	26	77	23			
26-27	25	64	36			
28-30	29	40	60			
31-40	43	20	76	4		
41-50	6		100			
Total	367					

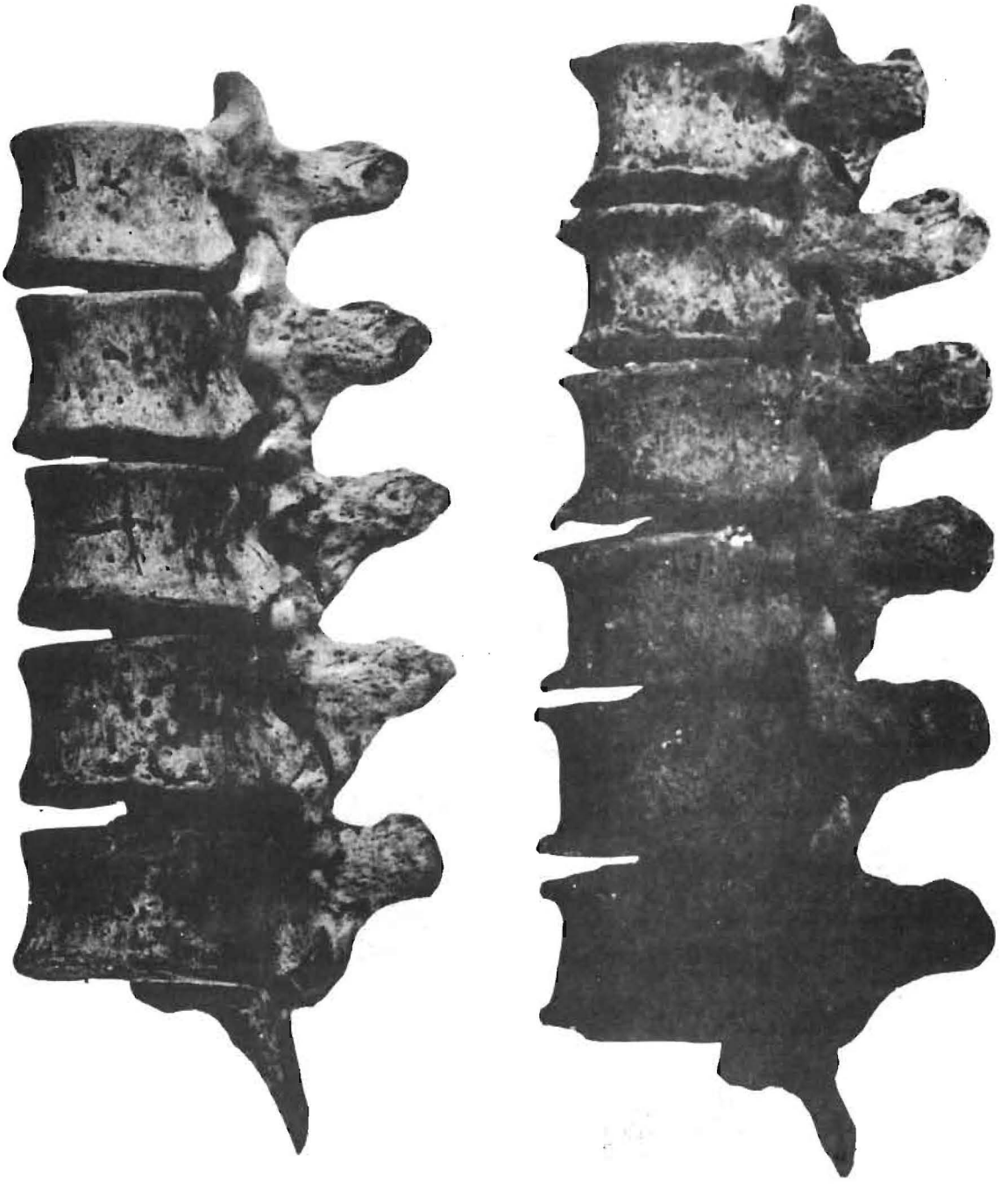

Fig. 53 Lateral anterior view, as articulated, of selected vertebrae showing: Left: no lipping at anterior margins, T-3 to T-7 (No. 118, 22 years). Right: marked lipping at anterior margins, T-4 to T-9 (No. 360, 32 years).

from the age of 22 and reaches 60 percent at 30 years of age. Above 30 years, lipping extends in a few cases to most of the cervical and all of the thoracic and lumbar vertebrae (Fig. 53).

The distribution of vertebral lipping, as shown in Table 36, is rather erratic, especially in the age groups up through 22 years, but the highest percentages are concentrated in the lower thoracic region (T-10 and T-11). It must be pointed out, however, that much of the erratic nature of the data in Table 36 is probably due to cases where lipping was caused by local injury. Without reliable medical histories or without better evidence of injury, it is seldom possible to separate evidence of local trauma from injury caused by normal mechanical stress.

Lipping was also observed on the facet for the dens of the first cervical vertebra (Fig. 54) and was found to be too variable for useful age association. For example, in each age group from 17 to 50 the occurrence ranges from no lipping to extreme lipping and seems to be more of an individual characteristic than an orderly age change.

In general, the occurrence of lipping in the presacral vertebral column, though progressive and somewhat localized to the areas of greatest mobility, exhibits a high variability that cannot be adequately or usefully applied to estimations of age.



Fig. 54 Posterior superior view of the first cervical vertebra showing lipping of the facet for the dens. (No. 440, 31 years).

TABLE 36

AGE DISTRIBUTION OF VERTEBRAL LIPPING FOR THE SEPARATE ELEMENTS OF THE PRESACRAL COLUMN
(in %)

		Cervical							Thoracic												Lumbar				
Age	No.	1	2	3	4	5	6	7	1	2	3	4	5	6	7	8	9	10	11	12	1	2	3	4	5
17-18	55													4	4	2	2	2	2	4					2
19	52																2		2						
20	43								2	2	2			2		2	2		2						
21	37															3	3	3	5						
22	25														4				4				4	4	4
23	26									4	4	4	4	4	4	8	4	8	4	4	4				
24-25	26											4			4	4	4	8			4				
26-27	25					4	4			4	4	12	4	8	8	12	8	12	4						
28-30	29				3	3					6	13	10	20	20	33	30	23	13	23	3				
31-40	43			2	4	11	9	4	4	9	20	40	43	30	32	46	43	51	46	34	23	16	11	19	20
41-50	6					16				16	16	66	33	33	50	50	50	50	50	66	33	66	66	66	66
Total	367																								

7. Laminal Spurs

Bony spurs are often observed projecting from the laminae of the thoracic vertebrae (Fig. 55). These spurs have been described in detail by Le Double (1912) and Shore (1931). However, the reason or reasons for their occurrence was not known until 1938 when Naffsiger, Inman and Saunders pointed out that they represent normal ossifications functionally associated with the interlaminar ligaments. Allbrook (1954) and Davis (1955) have also investigated various aspects of spur formation but no one has correlated this phenomenon with age.

Laminal spurs were observed in a large portion of the series under discussion and, although present on both superior and inferior borders, only those on the superior borders were recorded. The results are summarized in Tables 37 and 38.

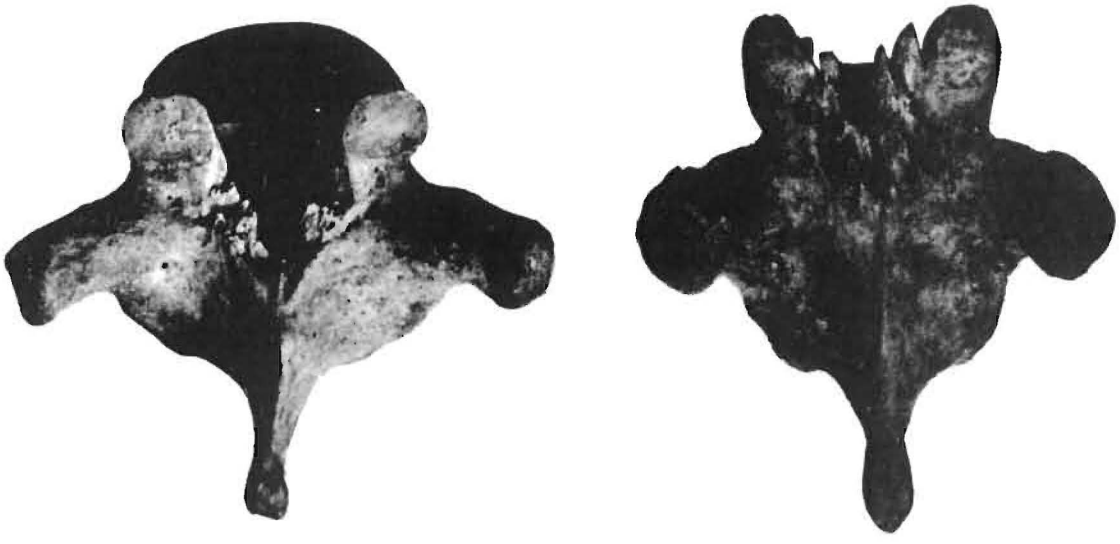

Fig. 55 Posterior.superior view of two thoracic vertebrae showing: Left: slight projecting bone spurs of the 7th thoracic (No. 51, 18 years); Right: extreme projecting bone spurs of the 8th thoracic (No. 314, 21 years).

From Table 37, two conclusions are immediately evident: 1) with the exception of a few cases, the cervical vertebrae do not seem to be involved, 2) the amount of individual variation makes it impossible to correlate the occurrence of spurs with age. We can state only that with advancing age, the spurs are more frequently present and especially in the lower thoracic region.

TABLE 37

AGE DISTRIBUTION OF THE OCCURRENCE OF LAMINAL SPURS FOR THE PRESACRAL COLUMN AS A WHOLE. (in %)

		Cervical							Thoracic												Lumbar				
Age	No.	1	2	3	4	5	6	7	1	2	3	4	5	6	7	8	9	10	11	12	1	2	3	4	5
17-18	55								9	14	18	25	30	29	25	27	27	34	40	30	10	9	3	1	1
19	52								9	19	25	30	28	28	36	36	30	40	38	19	13	13	7	3	2
20	43								11	18	29	39	49	39	46	51	53	58	55	49	16	14	4		
21	37							3	13	24	40	40	40	45	51	51	45	48	55	32	8	10	8	3	3
22	25								24	36	32	36	40	44	44	48	48	52	52	52	36	20	5		
23	26						4	4	30	46	53	53	53	53	61	61	69	69	61	53	34	30	15	11	4
24-25	26							4	11	46	61	65	69	80	73	84	73	80	84	77	46	50	19	15	7
26-27	25								12	28	48	52	56	60	60	56	56	68	68	60	28	24	8	8	12
28-30	29							3	36	46	56	63	63	56	66	70	73	73	76	70	36	30	23	20	16
31-40	43							4	14	44	58	74	65	67	67	69	74	74	74	74	49	30	20	20	14
41-50	6								33	50	50	66	66	50	66	83	83	93	100	66	50	33	16		
Total	367																								

To determine the area of most pronounced expression, the age distribution for the two most extreme stages of development (3 and 4) are summarized in Table 38. Again, individual variation makes it difficult to extract any significant trend. Since examples of the pronounced development of spurs can be found in all age groups from 17 to 50 and the occurrence of this feature ranges from T-3 to T-12, there seems to be no practical correlation between the bony spurs and age.

TABLE 38

AGE DISTRIBUTION FOR STAGES 3-4 OF VERTEBRAL SPURS IN THE THORACIC VERTEBRAE.
(in %)

		Thoracic Vertebrae											
Age	No.	1	2	3	4	5	6	7	8	9	10	11	12
17-18	55						2	2	2	2	3	2	2
19	52			2	2	2	5	3	5	3	2	7	2
20	43				2								2
21	37							3	5		3	3	
22	25								8	8	16	14	5
23	26					4	11	8	8	11	11	18	
24-25	26					4	4	11	11	11	15	15	8
26-27	25							5	14	8	16	20	8
28-30	29			3	3	10	10	6	6	10	6	6	3
31-40	43			2		4	11	14	16	16	20	23	7
41-50	6						16	33	33	33	33	50	16
Total	367												

8. Summary

The presacral vertebral column is completely ossified by the 24th year. Noteworthy is the sequential pattern of ossification which shows the last signs of complete maturity occurring in the upper thoracic vertebrae (specifically, T-4 and T-5).

Striations tend to disappear from the surface of the centra, starting at 23 years of age, but may persist in the lumbar region for many years. Other age changes, in the form of lipping of the anterior borders and the formation of spurs on the laminae of the dorsal arches, show a progressive increase in their occurrence and gross development. However, all are too variable to be of much assistance in age identification.

CHAPTER VII

SCAPULA

1. Introduction

The scapula is a triangular-shaped bone forming the posterior end of the shoulder girdle. It is held in place largely by muscle but also by articulations with the head of the humerus at the glenoid fossa and with the clavicle at the acromial process.

Normally the scapula presents 6 epiphyses: two for the coracoid process and one each for the margin of the glenoid cavity, the acromion, the inferior angle, and the medial or vertebral border. However, since the epiphyses for the coracoid process and glenoid fossa usually unite before the beginning age of our series (Fig. 56), only the remaining 3 were observed and their union recorded.

The acromial epiphysis and the epiphysis of the inferior angle are easily seen and recorded. On the other hand, the epiphysis of the medial border presents an observational problem; it is either a long, narrow and very fragile strip of bone, or reduced to small segments (Fig. 57), and is frequently damaged, especially before union is complete. We feel, therefore, that our recordings of stages of union for this epiphysis may, in some cases, be incorrect and the results should be viewed with this in mind.

In addition to the above information, direct observations were made on age changes in the surfaces of the acromial facet and glenoid fossa.

2. Historical Remarks

The majority of studies on the scapula emphasize the comparative morphology or pathology and few, if any, consider the pattern of ossification. This scarcity of information on ossification is reflected in the anatomy textbooks (Grey, Morris and Cunningham, to mention a few) where it is simply stated that the epiphyses of the scapula are joined by the 25th year.

It was not until the 1920's, when the Western Reserve collection was formed, that the subject of epiphyseal maturation in this bone could be adequately analyzed. Using this collection of documented skeletons, Graves, in 1922, and Stevenson, in 1924, reached practically the same conclusions. Graves observed the age changes in 139 pairs of scapulae

Fig. 56 Proximal end of left scapula showing last stages of union for the epiphysis of the glenoid fossa (only case found in our series). (No. 317, 18 years).

Fig. 56 Proximal end of left scapula showing last stages of union for the epiphysis of the glenoid fossa (only case found in our series). (No. 317, 18 years).

Fig. 57 Right scapula showing the epiphysis of the medial border reduced to small segments. (No. 328, 38 years.)

ranging in years from 18 to 88 and concluded (p. 21) that the several epiphyses unite at different ages, "...finally producing an adult scapula in every detail by approximately the 22nd year of life..." Two years later, Stevenson, working with a sample of 110 pairs from ages 15 to 28, concluded (p. 70) that, "The date of union for these (epiphyses) varies in different individuals between the nineteenth and twenty-second years."

We will now add our observations for comparison.

3. Epiphyses for the Acromion, Inferior Angle and Medial Border.

Table 39 summarizes the 4 stages of epiphyseal maturation for the 3 epiphyses under consideration. With the exception of 6 cases in which the acromial epiphysis was united on one side but not on the other, significant differences in stages of maturation between right and left scapulae were not found. Thus, side is disregarded in this table.

TABLE 39

AGE DISTRIBUTION OF STAGES OF EPIPHYSEAL UNION FOR THE ACROMION, INFERIOR ANGLE AND MEDIAL BORDER OF THE SCAPULA.
(in %)

		Acromion					Inferior Angle					Medial Border				
Age	No.	0	1	2	3	4	0	1	2	3	4	0	1	2	3	4
17	10	50	-	-	10	40	50	10	-	-	40	60	-	-	10	20
18	38	20	4	4	8	64	38	8	2	12	40	46	10	8	10	26
19	51	10	2	2	4	82	21	-	4	11	64	30	-	10	15	46
20	43	4	-	2	11	83	9	-	-	4	87	7	5	5	13	70
21	37	-	-	-	5	95	5	-	2	2	91	-	6	10	13	71
22	24	4	-	-	-	96	-	-	4	-	96	-	4	4	4	88
23	26	-	-	-	-	100	-	-	-	-	100	-	-	-	-	100

Total 229

From Table 39, it is evident that union commences for all three epiphyses prior to the starting age of the present series (17 years) and finishes in the 23rd year. The progress of union is irregular throughout the age groups owing, perhaps, to the difficulties of observation mentioned. Graves and Stevenson also noted this irregularity. However, in spite of irregularity and rapidity of union, there is some evidence indicating a sequence. Even though all three are completely fused at the same age, the epiphyses for the acromion and inferior angle show concentrated activity in the ages of 18 to 20 whereas the epiphysis for the medial border demonstrates a lag in progress that lasts through the age of 22.

Infrequently the acromial epiphysis fails to unite altogether. Earlier reports of separate acromial bones by Symington (1900), Vallois (1932) and Gray (1942) give frequencies of occurrence of 6.2, 2.7 and 3.3 percent respectively. This feature is represented in our series by a single case in an individual 37 years of age (Fig.58). It is necessary to be aware of this anomaly in order to avoid mistaking it for evidence of immaturity.

4. Changes in Joint Surfaces

As already noted, the scapula presents 2 joint surfaces: a facet on the acromion for articulation with the clavicle, and the glenoid fossa for articulation with the head of the humerus. Normal wear to these surfaces during the life span of the individual produces various changes, but mainly lipping of the joint margins (Fig. 59). Since lipping is often taken into consideration in estimating skeletal age, observations on its frequency at these sites are presented in Table 40.

TABLE 40

AGE DISTRIBUTION OF STAGES OF LIPPING FOR THE CLAVICULAR FACET AND GLENOID FOSSA. (in %)

		Clav. Facet Lipping					Glenoid Lipping				
Age	No.	0	1	2	3	4	0	1	2	3	4
17	10	90	10	-	-	-	30	70	-	-	-
18	38	84	16	-	-	-	72	28	-	-	-
19	51	75	23	2	-	-	44	54	2	-	-
20	43	66	32	2	-	-	46	54	-	-	-
21	37	55	40	5	-	-	51	44	5	-	-
22	24	55	41	4	-	-	50	50	-	-	-
23	26	54	42	4	-	-	32	57	11	-	-
24-25	27	51	45	4	-	-	55	41	4	-	-
26-27	25	20	44	28	8	-	40	28	24	4	4
28-30	29	54	37	9	-	-	41	43	16	-	-
31-40	42	28	57	11	2	2	16	52	23	9	-
41-50	6	33	16	51	-	-	-	34	33	33	-
Total	358										

Fig. 58 Left scapula showing failure of acromial epiphysis to unite. (No. 122, 37 years).

Fig. 59 Left scapula showing lipping of the glenoid margin. (No. 360, 32 years).

As will be seen, beginning lipping is present in both joints throughout the series. In the glenoid fossa this amounts to very little more than a slight angulation of a previously rounded margin. Although the percentages in Table 40 are erratic (due in some part to subjectivity of observation), they show a general increase with advancing age. It should be noted also that 2nd-degree lipping does not begin until the late teens and high frequencies of this stage do not appear until the middle 20's. We can conclude therefore, that lipping of the scapular joints progresses too slowly to be of much help in age identification except as it may substantiate or support other ageing criteria.

5. Summary

Since the epiphyses for the caracoid process and glenoid margin usually unite before the beginning age of our series, stages of union were recorded only for the acromion, inferior angle and medial border. Though the epiphysis for the medial border lags in the early twenties, fusion for all three is completed by the 23rd year.

The occurrence of lipping on the acromial facet and glenoid fossa cannot be used for other than supportive age evidence.

CHAPTER VIII

STERNUM

1. Introduction

Morphologically the sternum is the most variable bone in the body. According to Ashley (1956), a very definite relationship exists between the shape of the adult sternum and the number and arrangement of the ossification centers from which the bone develops. Most of this variation involves the middle portion of the bone, the corpus sterni; the form of the superior portion, the manubrium sterni, is much more constant; that of the inferior portion, the xiphoid process, is inconstant (it has been largely disregarded in the present study). At the beginning age of the Army series (17-18 years) the sternum usually consists of a manubrium and a still-subdivided corpus sterni (with as many as three parts and sometimes with traces of other previously separate parts).

The joint between the manubrium and the corpus sterni, known as the manubriogladiolar or superior intersternal joint, is, of course, unpaired (although the second pair of ribs are attached here). Otherwise there are usually 8 paired joints formed by the clavicles and the first 7 ribs. Although there are thus 17 joint areas providing age indications, only 5 (one unpaired, 4 paired) have been utilized in the present study. The observed paired joints are the sternoclavicular and the first, third and fourth chondrosternals. In addition, the so-called interarticular groove between the sternoclavicular and first chondrosternal joints on each side was observed. Each feature was rated on the usual scale of 0-4. These readings were supplemented with a photograph of the whole sternum (usually only the anterior surface) and by a cast of one lateral side of the manubrium (both sides were cast when they were asymmetrical, and sometimes a cast was made of one side of the corpus sterni).

Attention is called to the fact that the superior intersternal joint and the paired first chondrosternal joints are usually synchondrodial in type: that is, they lack joint cavities, cartilage being joined directly to bone. The paired sternoclavicular and other chondrosternal joints are diarthrodial, having well-defined joint cavities. It is noteworthy also that (Stewart 1954, p. 521) "on each side the joints for the clavicle and first rib, which differ in type (see above), are contiguous, whereas the joint for the second rib is located at the junction of the manubrium and corpus

and hence in close relationship with the superior intersternal joint (again 2 joints of different type in juxtaposition)".

2. Historical Remarks.

In 1890 Thomas Dwight, Professor of Anatomy at Harvard University, investigated the sternum from the identification standpoint. He concluded that, "The sternum is of little value as an index of age" (p. 532). Perhaps because of this discouraging report, no one else seems to have studied age changes in the sternum until 1954, when Stewart published his preliminary report on "Metamorphosis of the joints of the sternum in relation to age changes in other bones." The latter study was undertaken to explore the possibility of including the sternum in the present work on the remains of American soldiers. In order to evaluate the findings on the soldiers, the summary of the 1954 findings, which was stated in very tentative terms, is quoted here:

> 1. Up to the time the proximal epiphysis of the humerus is uniting (up to 17-18? years).
>
> Component elements of the corpus sterni are still identifiable, although those in the inferior two-thirds may have fused. Joint surfaces here and in the manubrium are rounded, dimpled or billowed, and exhibit a matte-like surface texture.
>
> 2. Coincident with, and somewhat following, the union of the proximal epiphysis of the humerus (about 19-20? years).
>
> Epiphyseal plates can be found in all stages of union on the clavicular facets. At the end of this period epiphyseal plates are beginning to unite on the rib facets, or failing the formation of plates, the articular surfaces are beginning to glaze over. Also, in most cases, the superior element of the corpus is fusing with the element next below.
>
> 3. Coincident with the union of the epiphyses for the iliac crest and ischial ramus (about 20-23? years).
>
> The eminence marking the boundary between the articular areas of the clavicle and first rib gives way to a sharp transverse ridge. The last step in the formation of this ridge is the filling-in of a ventral interarticular notch. At this time the facets for the third ribs are usually divided by a transverse cleft, the last remaining

sign of the recent fusion of the superior element of the corpus.

4. Coincident with and immediately following union of the epiphysis at the sternal end of the clavicle (about 20-30? years).

Raised rim is formed around the articular areas of the first and second ribs and those of the superior intersternal joint. By this time the superior intersternal joint has broadened so that the articular surfaces are rectangular. Facets for first ribs become slightly more porous. Clefts in facets for third ribs are being bridged across ventrally and dorsally.

5. Just before or coincident with the appearance of arthritis in the vertebrae (about 35 years).

Hypertrophic bone spurs appear around the margins of the facets for the first ribs, particularly ventrally and dorsally and more above than below. The other rib facets develop spurs much more slowly. Also, there may be progressive, disorderly break-down of the joint surfaces.

3. Fusion of primary elements

As pointed out in the introduction, the corpus sterni at 17 years of age usually is still in two or more parts. Thereafter the fusion which has taken place in the lowermost segments moves upwards to bring about the incorporation of the remaining segments. Table 41 shows the progress of fusion between the second and third segments (at the level of the attachment of the fourth ribs)* during the interval from 17 to 25 years. The distinction between recent (stage 3) and complete (stage 4) fusion is often difficult to determine. In general, stage 4 was assumed to have been reached when no cleft remained at the bottom of the costal notch, or when such a cleft, although present, was bridged over and otherwise looked mature. Evidence of immaturity often is more visible posteriorly than anteriorly. Figure 60 shows such a case involving the next highest level. As will be seen from the table, 72.7% of the 17-18 year group had reached the third and fourth stages of fusion. Not until 23 years were 100% of cases in these stages. In view of this situation perhaps an equally significant finding is that nonunion at this level may exist up to the age of 22. Figure 61 shows an example of such nonunion at this age.

Fusion of the primary elements of the corpus at the next highest level, that is, between the first and second segments (level of attachment of the third ribs) follows a later and slower course. Table 42

*The segments, like the ribs, are numbered from above downward.

TABLE 41

PROGRESS OF FUSION BETWEEN SECOND AND THIRD SEGMENTS OF THE CORPUS STERNI (AT LEVEL OF ATTACHMENT OF FOURTH RIBS). (in %)

Age	No. of Cases	No Fusion	Beginning Fusion	Active Fusion	Recent Fusion	Complete Fusion
17-18	44	9.1	9.1	9.1	68.2	4.5
19	42	11.9	-	4.8	69.0	14.3
20	36	5.6	-	-	55.6	38.9
21	37	8.1	2.7	2.7	48.6	37.8
22	22	4.5	-	-	45.4	50.0
23	24	-	-	-	50.0	50.0
24-25	24	-	-	-	8.3	91.7

TABLE 42

PROGRESS OF FUSION BETWEEN FIRST AND SECOND SEGMENTS OF THE CORPUS STERNI (AT LEVEL OF ATTACHMENT OF THIRD RIBS). (in %)

Age	No. of Cases	No Fusion	Beginning Fusion	Active Fusion	Recent Fusion	Complete Fusion
17-18	46	45.6	2.2	13.0	34.8	4.3
19	43	27.9	-	13.9	51.2	7.0
20	38	13.2	5.3	7.9	52.6	21.0
21	38	13.2	-	7.9	52.6	26.3
22	23	8.7	-	4.3	56.5	30.4
23	24	16.7	-	-	58.3	25.0
24-25	24	-	-	4.2	41.7	54.2
26-27	25	12.0	-	-	36.0	52.0
28-30	29	3.4	-	-	37.9	58.6

summarizes the progress of fusion at this level during the interval from 17 to 30 years. Fusion here makes the corpus sterni one piece of bone. As will be seen from this table, the combined stages of recent and complete fusion has been reached in 39.1% of the cases by 17-18 years. Thereafter the percentage rises but does not reach 100%, because unlike in the preceding table there is evidence in Table 42 of persistence of nonunion in a few cases. Figure 62 shows such a case persisting to the age of 27 years. On the other hand, some of these cases of nonunion at the level of attachment of the third ribs are to be accounted for by the presence of an anomaly in which the segment that would normally fuse with and form

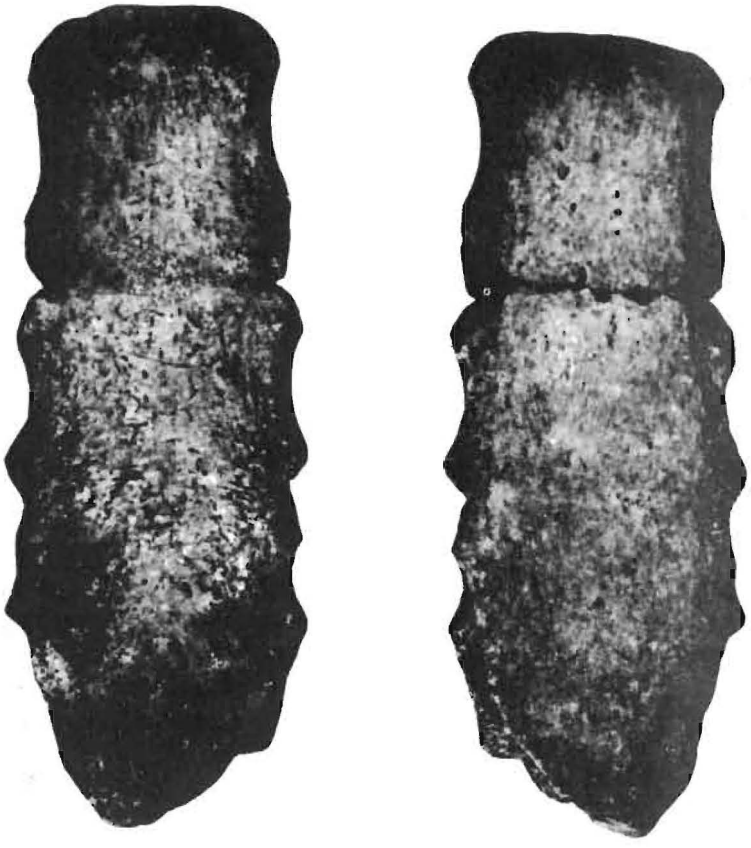

Fig. 60 Anterior and posterior views of the corpus sterni in case No. 386 (unidentified) showing that union of the top segment may be delayed posteriorly.

the uppermost part of the corpus instead fuses with the bottom of the manubrium, thus producing an unusually long manubrium. Examples of such anomaly are shown in Figure 63. Except for anomalous cases which can often be identified because of signs of advanced maturation elsewhere in the bone, it would seem that nonunion is absent after 22 years of age. On the other hand, attention is called to the fact that signs indicative of stage 3 can be found throughout the third decade (Fig. 64).

Normally the joint between the manubrium and corpus sterni, the so-called superior intersternal joint, does not fuse. However, in the preceding paragraph it has been pointed out that the manubrium sometimes captures the uppermost segment of the corpus. Also, occasionally there is fusion between the manubrium and the corpus as a whole. Trotter



Fig. 61 An example of delayed union of the segments of the corpus sterni. (No. 83, 22 years.)



Fig. 62 Example of delayed union of the top segment of the corpus sterni. (No. 420, 27 years).

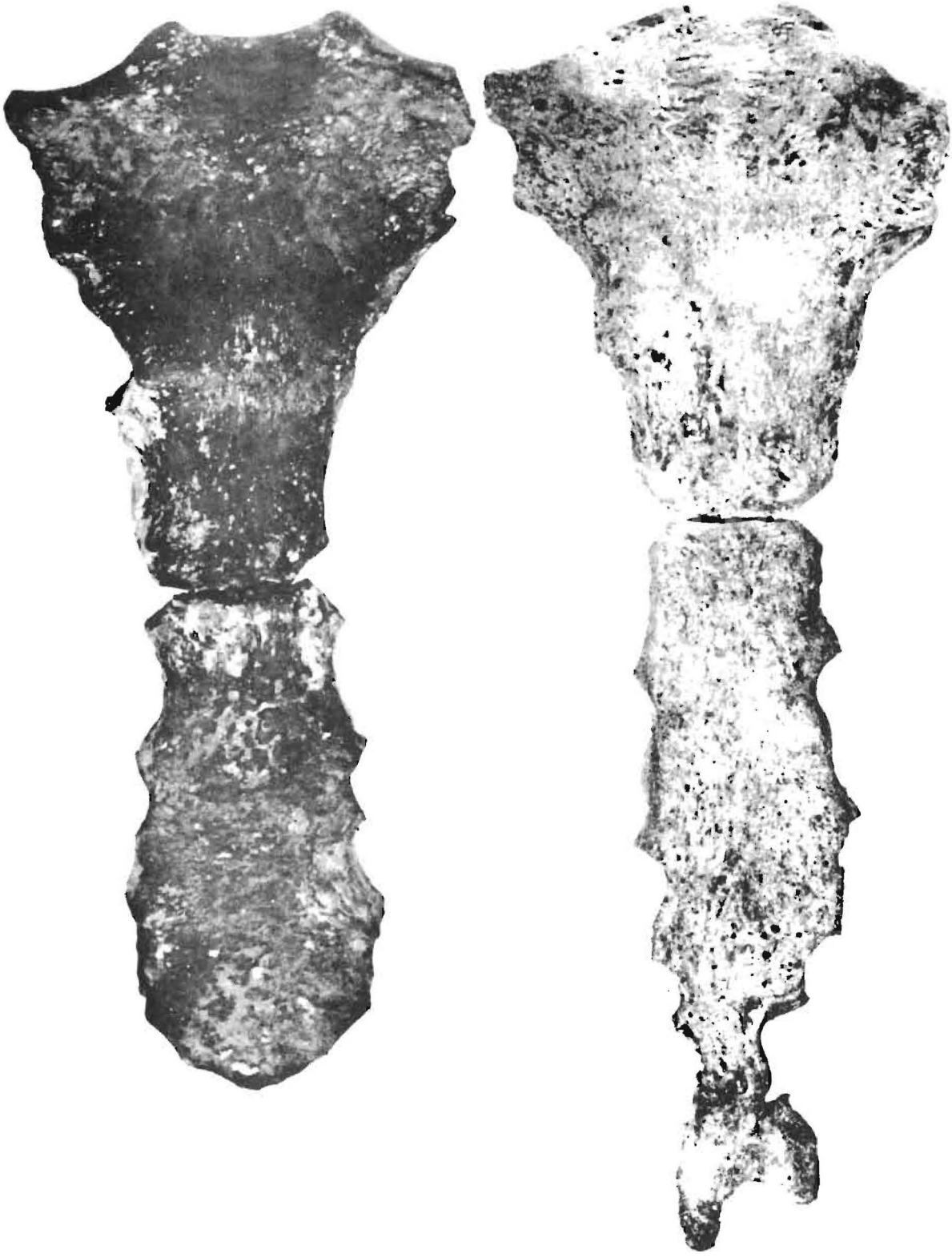

Fig. 63 Examples of extra long manubria in which it appears that the segment that normally fuses with and forms the uppermost part of the corpus instead has fused with the bottom of the manubrium. (Left: No. 413, 28 years; Right: No. 109, 30 years).



Fig. 64 Signs of recent union (stage 3) of the first and second segments of the corpus sterni in an individual 25-28 years of age. (No. 424, POW, exact date of death uncertain).

(1934) found that such fusion occurred in 5.7% of cases up to the age of 30 and in 10.3% of cases between 30 and 60. Thus the correlation with age is very low. As will be seen from Table 43, our total series yields a frequency of 5.2% of such fusions. According to this table also a thickening of the joint surface, usually with a breakdown of the surface (Fig. 65, middle), occurs in 13% of cases. In none of these, of course, is the joint fused. However, since most fused superior intersternal joints are thickened (Fig. 66), it would seem likely that thickening and surface breakdown are preliminary stages of fusion at this level. We feel that when no thickening can be detected in a fused superior intersternal joint, the manubrium could have been of the anomalous type described earlier. Joint thickening does not seem to occur at other segmental levels (Fig. 65, right).

TABLE 43

THICKENING AND FUSION OF SUPERIOR INTERSTERNAL JOINT BY AGE
(in %)

Age	No. of Cases	No Fusion	Joint thickened but not fused	Fusion
17-18	52	90.4	9.6	-
19	46	84.8	13.0	2.2
20	44	86.4	9.1	4.5
21	38	84.2	10.5	5.3
22	23	82.6	17.4	-
23	24	66.7	25.0	8.3
24-25	26	76.9	7.7	15.4
26-27	25	88.0	4.0	8.0
28-30	30	80.0	6.7	13.3
31-40	43	62.8	32.6	4.6
41-50	6	66.7	33.3	-
Unknown	72	87.5	8.3	4.2
Means		81.8	13.0	5.2
TOTAL	429			

4. The Clavicular Notch

As pointed out by Stewart in 1954, an incompletely attached epiphysis sometimes is to be seen on the surface where the clavicle articulates (Fig. 67). This epiphysis may be so thin and scale-like that its presence is not readily detected. Also, since this feature is seen infrequently, the possibility exists that, like the epiphysis on the medial end of the clavicle, it may be greatly reduced in size or may not develop at all in some cases. Be this as it may, before epiphyseal union or its equivalent,

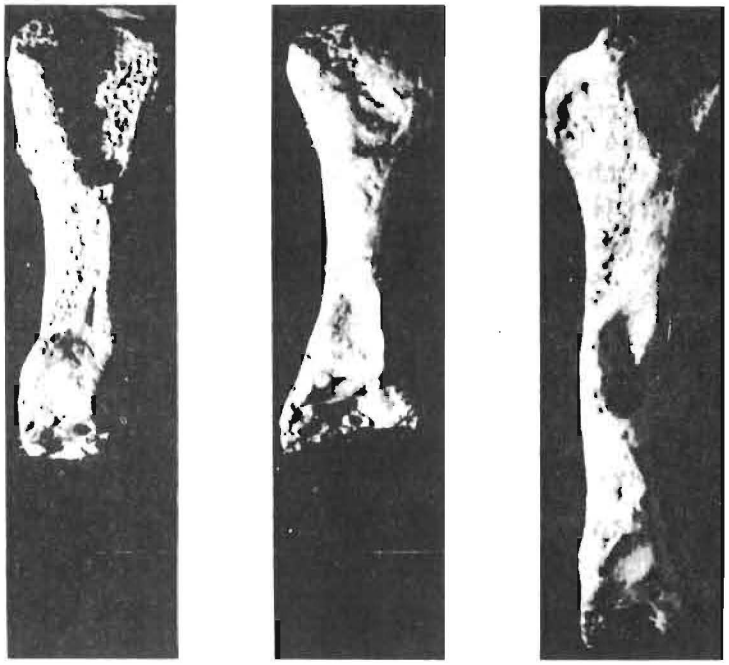

Fig. 65 Casts of the left side of 3 manubria showing variations at the level of the costal I notch. Left and middle: Normal and thickened superior intersternal joints, respectively. Right: A manubrium with a captive upper segment of the corpus but no thickening at the level of fusion. (Nos. 445, 81 and 413, respectively, all 28 years).

the surface is somewhat irregular, being dimpled or billowed, but seldom quite as much so as most other such surfaces (Fig. 68). Thus, in scoring the notch, any suggestion of billowing was rated as stage 1, and a visible epiphysis was rated as stage 2. Originally an effort was made to distinguish also stages 3 and 4 (that is, nearly and completely mature notches), but it was soon realized that these stages are not distinguishable and any opinion thereon is based on a knowledge of maturation events in other parts of the skeleton.

Table 44 shows the progress of maturation, as thus defined, in the clavicular notch from 17 to 23 years. It should be borne in mind that these results represent scorings made over a period of several months without any opportunity for reassessment. If the specimens had been available for review, it is possible that more individuals might have

Fig. 66 Three cases of synostosis between the manubrium and the body of the sternum showing different degrees of joint thickening. (Left: No. 314, 21 years; Middle: No. 396, unidentified; Right: No. 361, 39 years).



Fig. 67 Example of large epiphyses attached to clavicular notches of manubrium. In this case also, the manubrium is extra long and like those shown in Fig. 63. (No. 2, 19 years).

Fig. 68 Cast of the right side of the manubrium (No. 317, 18 years) showing the clavicular notch in the billowed stage prior to epiphyseal union. The billowing in this case is more prominent than usual.

been judged to be in the stage prior to epiphyseal union. Nevertheless, it seems likely that the date of the union of this epiphysis centers around 19 years. This opinion is supported by four other cases which have remained unidentified but which show stages of skeletal maturation comparable to those found in the 19-20 year group. Since the presence of an epiphysis was noted in such a small number of cases (and it was looked for specifically), it appears to have rather little utility in age identification. Examples of clavicular notches with epiphyses present are shown in Figure 69.

TABLE 44

PROGRESS OF MATURATION OF THE CLAVICULAR NOTCH
(in %)

Age	No. of Cases	Epiphysis Ununited	Epiphysis Uniting	Surface Essentially Mature
17	9	33.3	-	66.7
18	35	2.8	5.7	91.4
19	43	-	9.3	90.7
20	42	-	4.8	95.2
21	36	-	2.8	97.2
22	19	-	5.3	94.7
23	23	-	-	100.0

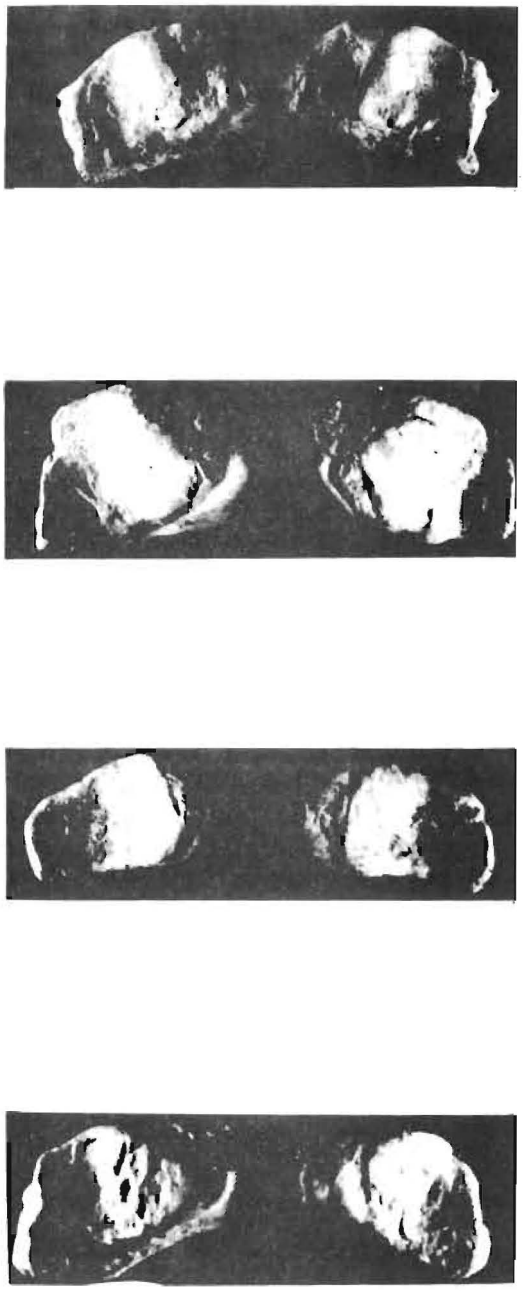

Fig. 69 Casts of the superior surface of 4 manubria showing epiphyses nearly united in the clavicular notches. (Top to bottom: No. 320, 19 years; No. 207, 21 years; No. 430, 19 years; No. 195, 18 years).

5. Costal I Notch

As pointed out in the introduction, the first ribs join the sternum through cartilaginous extensions (synchondroses) which are contiguous with the diarthrodial clavicular attachments. As a result of this difference in joint structure the typical costal I notch, when mature, displays a roughened and porous surface, whereas the clavicular notch has a smooth and compact surface. Occasionally, however, the surface of the costal I notch, especially in its superior part, displays a texture indistinguishable from that of the clavicular notch (Fig. 70). Presumably this altered surface represents an extension downward from the clavicular notch of the diarthrodial joint structure. In anomalous cases of this sort, maturational changes are obscured and seldom can be interpreted. Also, the porous surfaces of typical costal I notches, especially before they are fully mature, are vulnerable to weathering, with consequent loss of maturational detail. In the present series, as Table 45 shows, anomalous and weathered costal I notches are present and are the reason for eliminating a high percentage of