CHAPTER II

ERUPTION OF THE THIRD MOLARS

It is generally recognized that the eruption pattern of the third molars is extremely irregular. Yet, partly because of this irregularity and partly because of the late date of eruption, little specific information is available. Most of the studies on the time of eruption of the permanent teeth in the American population have been based on groups of school children, extending upwards in age to around 20 years (Cf.Bean, 1914, 1917; Cohen, 1928; Hurme, 1948; Suk, 1920). Since the full picture of third molar eruption is not yielded by groups with this upper age limit, the third molar usually has been excluded from such studies.

This situation is reflected in many textbooks where the eruption of the third molars is stated as a time interval rather than a mean age. For example:

Textbook	Age of eruption for third molars.
Cunningham's Text-Book of Anatomy	17 - 21
Grey's Anatomy	17 - 25
Hrdlicka's Practical Anthropometry	18+

On the other hand, although Steggerda and Hill (1942) likewise give an interval of 17 - 21 years, they state that this represents the period in which the greatest intensity of eruption occurs and does not include the upper time limit. Actually, it is not clear that their sample included individuals over 21 years of age. Obviously, such data are of limited use in cases of individual identification.

Besides erupting late and slowly, the third molars often do not erupt normally. This is especially true in the lower jaw where, because of an evolutionary reduction in length, the third molars may be forced out of normal alinement. A frequent result is that the lower third molars abut against the second molars, a condition known as impaction. In other cases the third molars, both upper and lower, may fail to erupt or even fail to form (congenital absence). In such cases during life, gross inspection may not reveal the presence of

some or all of the third molars and hence they may be reported as absent when in fact they are only hidden.

Despite these irregularities, the fact that the eruption of the third molars is one of the last maturational events, makes it a possible supplementary age indicator. For efficient use however, we must know not only the true range of eruption time in the American population but just when and how often the third molars appear in an eruptional stage that is meaningful for ageing purposes.

When present, a third molar may be in one of 4 positions: 1) still unerupted; 2) erupting; 3) impacted, and 4) normally erupted. When not present, a third molar may not have formed or may have been extracted antemortem. No attempt was made in the present study to identify the cause of the absence. The frequency of these 5 categories is given in Table 17. Here, we are particularly interested in the unerupted and partially erupted teeth, because they alone indicate immaturity. At 17 - 18 years, 55 - 58 percent of the upper third molars and 32 - 36 percent of the lowers are in these stages. These figures are reduced by nearly half (to 33 - 35 and 18 - 20 percent respectively) by age 19. After the age of 22, eruption has terminated except in a few cases which linger until 35 years.

The difference in eruptional incidence between upper and lower jaws is accounted for by impacted third molars occurring frequently in the lower jaw between the ages of 17 and 21 years. Due perhaps to natural loss of teeth and extractions, few cases of impactions were seen after the age of 21.

The significance of these data is twofold: 1) although the main eruptional period for the third molars is 17 - 22 years, at the peak of eruption (17 - 18 years) only a little over half of the uppers and a third of the lowers give a clue to age; and 2) although, for practical purposes, eruption ceases at 22 years, a few cases may be found in unerupted and erupting stages as late as 35 years. These data bear out our earlier statement that the third molars, particularly in the White race, are merely supplementary age indicators.

TABLE 17

THE STATUS OF THE THIRD MOLARS BY AGE GROUPS
(in %)

		Unerupted				Partially erupted				Impacted				Normally erupted				Absent			
		Upper		Lower		Upper		Lower		Upper		Lower		Upper		Lower		Upper		Lower	
Age		R	L	R	L	R	L	R	L	R	L	R	L	R	L	R	L	R	L	R	L
17-18	55	18	20	18	13	40	35	18	14	-	-	18	22	20	19	28	21	22	26	18	25
19	52	6	2	4	-	29	31	16	18	-	-	12	16	40	42	38	37	25	25	30	29
20	45	5	7	5	6	24	20	5	8	-	-	14	15	54	50	54	47	17	23	22	24
21	39	3	-	-	6	8	13	13	11	6	3	11	11	39	58	46	34	44	26	30	38
22	25	-	-	-	-	8	16	8	8	-	-	4	-	52	52	56	48	40	32	32	44
23	27	4	-	-	-	-	-	-	4	-	-	-	4	59	70	67	66	37	30	33	26
24-25	28	4	4	4	4	7	7	7	10	10	-	14	-	27	40	32	43	52	49	43	43
26-27	25	4	-	-	-	4	8	-	-	-	-	4	4	32	36	44	44	60	56	52	52
28-30	29	4	-	-	4	4	7	4	11	-	-	4	-	55	55	56	44	37	38	36	41
31-40	43	2	2	-	2	2	7	2	-	5	-	5	5	45	44	40	45	46	47	53	48
41-50	6	-	-	-	-	-	-	-	-	-	-	-	-	33	17	33	17	67	83	67	83
Total	375																				

CHAPTER III

EXTREMITIES

1. Introduction

The three major bones making up each of the four extremities are called the "long bones." Each long bone is made up of a diaphysis (shaft) with one or more epiphyses at either end. Thus, the long bones grow in two dimensions; in girth and in length (by means of the epiphysis). Growth ceases when the epiphysis joins or fuses with the diaphysis.

Although the long bones of the present series presented 15 observable epiphyses, considerations of space on the data card set a limit on the number that could be recorded in detail. Thus, only those epiphyses with the longest period of activity in the military age range were placed on the card. The status of all other epiphyses was recorded in the form of notes supplemented by photographs. This procedure resulted in a division of the epiphyses into two groups as follows:

Group I. (Epiphyses showing early union)
- Upper extremity
  - Elbow joint:
    - Distal epiphysis of humerus
    - Medial epicondyle of humerus
    - Proximal end of radius
    - Proximal end of ulna
- Lower extremity
  - Hip joint:
    - Head of femur
    - Greater trochanter of femur
    - Lesser trochanter of femur
  - Ankle joint:
    - Distal end of tibia
    - Distal end of fibula

Group II. (Epiphyses showing delayed union)
- Upper extremity
  - Shoulder joint:
    - Proximal end of humerus
  - Wrist joint:
    - Distal end of radius
    - Distal end of ulna

Lower extremity
Knee joint:
Distal end of femur
Proximal end of tibia
Proximal end of fibula

In the 17 to 20 year age groups, 14 percent of cases show unattached epiphyses of the upper and lower extremities. Table 18 shows the distribution of such epiphyses as subdivided into Groups I and II. From this it appears that 20 years is the upper age limit where an observer can expect to find unattached epiphyses of the long bones. Also, the small representation of unattached epiphyses in Group I indicates that this group is the first to mature, thus substantiating the utility of the division.

TABLE 18

THE AGE DISTRIBUTION OF UNATTACHED LONG BONE EPIPHYSES IN THE PRESENT SERIES.
(in %)

Epiphyses	Age 17	18	19	20	21
Group I.					
Greater trochanter	-	2	-	-	-
Distal fibula	10	-	-	-	-
Group II.					
Proximal humerus	30	13	5	-	-
Distal radius	50	18	7	4	-
Distal ulna	50	24	7	4	-
Proximal tibia	10	7	2	-	-
Proximal fibula	40	11	4	-	-

2. Historical remarks

The age order of epiphyseal union for the bones of the extremities has long been of interest to anatomists. However, despite a seeming wealth of knowledge, it is extremely difficult to find agreement on ages of epiphyseal union. In a table entitled, "Ages assigned by various authorities for union of epiphyses," Stevenson (1924, p.54) pointed out this lack of agreement among 11 authors and went on to demonstrate the results of his work on 110 skeletons from the Western Reserve collection.

For the purpose of comparing observations made directly on bones, Stevenson's findings are generally considered the standard authority.

More recently, studies giving the age order of epiphyseal union have come from the analysis of roentgenographs (for example, Paterson, 1929 and Flecker, 1942). However, a disparity in results still remains, as is shown in Table 19 where the findings of these authors are compared with those of Stevenson. Actually, the differences shown in Table 19 are not as great as was demonstrated by Stevenson, although a difference of 5 years appears in the case of the medial epicondyle of the humerus. This variability in the stated times of epiphyseal union has made age estimation a difficult if not confusing process.

TABLE 19

AGES ASSIGNED BY THREE AUTHORS FOR UNION OF THE LONG BONE EPIPHYSES.

Epiphyses	Stevenson ('24)	Paterson ('29)	Flecker ('42)
Group I.			
Upper extremity:			
Med. epicond. of humerus	16	18-21	16
Prox. radius	18	18-19	16
Prox. ulna	16-17	19	16
Lower extremity:			
Head of femur	18	18	17
Gtr. troch. of femur	18	18	16
Lsr. troch. of femur	18	18	17
Dist. tibia	18	18	17
Dist. fibula	18	18	17
Group II.			
Upper extremity:			
Prox. humerus	20	21	18
Dist. radius	19	21	19
Dist. ulna	19	21	19
Lower Extremity:			
Dist. femur	19	18	19
Prox. tibia	19	19	18
Prox. fibula	19	18	19

A suggestion of the pattern shown in Table 18 is also seen here in Table 19. It can be calculated from the latter that the average age of union for Group I is 17.5 years while that for Group II is 19.0 years.

3. Upper extremities

Observations on the epiphyses of the long bones are summarized in Tables 20 and 21.

TABLE 20

THE AGE DISTRIBUTION OF COMPLETE UNION FOR THE LONG BONE EPIPHYSES OF GROUP I. (in %)

		Upper Extremity			Lower Extremity				
		Humerus:				Femur:			
Age	No.	med. epicond.	Radius: prox.	Ulna: prox.	head	gtr. troch.	lsr. troch.	Tibia: dist.	Fibula: dist.
17-18	55	86	93	90	88	88	88	89	89
19	52	96	100	100	96	98	98	98	94
20	45	100			100	100	100	100	100
Total	152								

The Humerus:

At 17 and 18 years of age, the distal epiphysis is completely united in all cases. On the other hand, the epiphyses for the medial epicondyle and the head of the humerus are incompletely united in 14 and about 79 percent of cases respectively. The former reaches complete union in all cases by the end of the 19th year and the latter in the 24th year.

The epiphysis for the medial epicondyle unites from below upward, thus leaving a small notch at the superior end as the last site of union (Fig. 12). The last site of union for the proximal end appears as a slight groove, postero-laterally (Fig. 13).

TABLE 21

THE AGE DISTRIBUTION FOR STAGES OF UNION FOR
THE LONG BONE EPIPHYSES OF GROUP II.
(in %)

		Upper Extremity															Lower Extremity													
		Humerus (prox.)					Radius (dist.)					Ulna (dist.)					Femur (dist.)					Tibia (prox.)					Fibula (prox.)				
		Stages					Stages					Stages					Stages					Stages					Stages				
Age	No.	0	1	2	3	4	0	1	2	3	4	0	1	2	3	4	0	1	2	3	4	0	1	2	3	4	0	1	2	3	4
17-18	55	14	5	25	35	21	22	3	14	32	29	29	1	11	24	35	16	2	3	18	61	2	2	7	23	66	14	-	3	12	71
19	52	5	2	10	58	25	7	-	5	48	40	7	-	5	32	56	4	-	1	9	86	1	-	1	17	81	4	-	6	4	86
20	45	2	2	4	40	52	4	-	2	24	70	4	2	-	24	70			2	9	89				13	87			2	-	98
21	37			2	27	71				19	81				10	90				8	92				5	95				5	95
22	24				12	88				12	88				8	92					100				4	96					100
23	26				4	96					100					100										100					
24+	136					100																									
Total	375																														

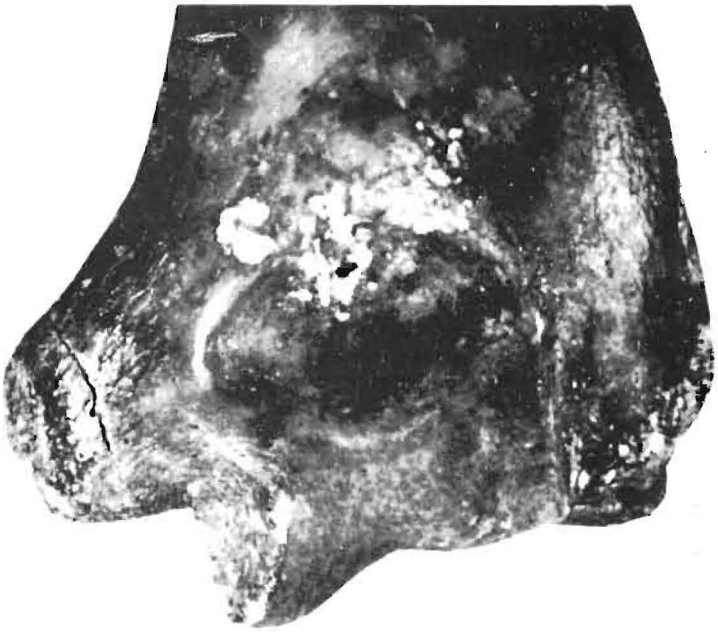

Fig. 12 Distal end of right humerus showing the epiphysis of the medial epicondyle in stage 2 of union. Note that union has begun inferiorly. (No. 44, 18 years).

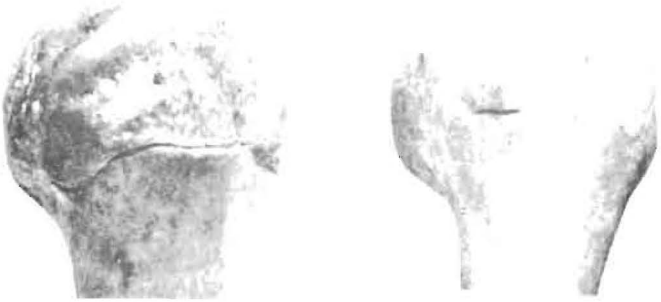

Fig. 13 Proximal end of right humeri showing late stages of union.
Left: Early stage 3 of union. (No. 97, 20 years).
Right: Late stage 3 of union. (No. 174, 20 years).

The Radius and Ulna:

The epiphyses of the radius and ulna can be conveniently treated together since they unite in pairs simultaneously. When first seen in our series, the proximal ends of the radius and ulna are in a late stage of fusion (Fig. 14). Both epiphyses are united in all cases by the 19th year. Early stages of union for the distal epiphyses occur from 17 - 20 years. Thereafter, all cases are either fused or in the last stages of closure. By 23 years, both distal epiphyses are completely united in all cases.

Last traces of the epiphyseal lines are usually located, for the distal ulna, at the base of the styloid process, postero-medially (Fig. 15) and for the distal radius, antero-laterally (Fig. 16).



Fig. 14 Proximal end of right radius (left) and ulna (right) showing recent signs of union. (No. 44, 18 years).

Fig. 15 Distal end of left ulna (posterior) showing stage 4 of union. (No. 99, 17 years).

Fig. 16 Distal end of left radius (anterior) showing stage 4 of union. (No. 250, 22 years).

4. Lower extremities

The Femur:

As seen in Table 21, the epiphyses for the head, and greater and lesser trochanters are in the last stages of union for most of the cases (more than 80 percent). Cases of non-union linger on until the end of the 19th year and by 20 the epiphyses for the proximal end of the femur are united in all cases. From Table 21 we find that the last of the femural epiphyses to fuse is at the distal extremity where ossification is still in early stages as late as 20 years and does not become complete for all cases until the 22nd year.

Fig. 17 Proximal end of the left femur showing the epiphyses for the head in stage 3 of union, while those for the greater and lesser trochanters are in stage 2 of union. (No. 72, 18 years.) Note that union begins for the head, antero-laterally; for the greater trochanter, antero-medially; and for the lesser trochanter, superiorly.

At the proximal end of the femur, the last sites of union for the three epiphyses are as follows: 1) head, postero-medially; 2) greater trochanter, postero-medially; and 3) lesser trochanter, inferior margin (Fig. 17). At the distal end, on the postero-medial side (just above the medial condyle), a fissure locates the last site of union (Fig. 18).

Fig. 18 Distal end of left and right femur showing stage 3 of union. (No. 319, 19 years).

The Tibia:

Early stages of fusion were found in the distal epiphysis through the 19th year and complete union for all cases occurs by the 20th year. At the proximal extremity, a few cases show early stages of union in the 17-19 year age groups. Thereafter, progress for completed union is slow and does not occur for all cases until the 23rd year.

Last traces of union at the distal end occur antero-laterally (unfortunately, we are unable to illustrate this feature from our photographs). At the proximal end, the last site of union is found postero-medially (Fig. 19). However, a well-marked groove may persist at this site of last union long after complete fusion has occurred (Fig. 20). Evidence of this groove has been found in tibiae as old as 37 years.

Fig. 19 Proximal end of right and left tibia showing stage 3 of union. (No. 153, 20 years).

Fig. 20 Proximal end of right tibia showing persistent groove at site of union. (No. 21, 24 years).

The Fibula:

The pattern of maturation for the distal epiphysis of the fibula corresponds with that of the tibia: early stages of union through the 19th year and complete union for all cases by the age of 20. The proximal epiphysis shows early stages of fusion as late as the 20th year and complete union for all cases does not occur until the 22nd year.

The last site of union at the distal end is located medially (Fig. 21); at the proximal end, antero-laterally (Fig. 22).

Fig. 21 Distal end of fibula (left medial and right lateral views) showing stage 2 of union. (No. 2, 19 years).

Fig. 22 Proximal end of right fibula showing stage 3 of union. (No. 89, 18 years).

5. Summary

At 17 and 18 years of age, the epiphyses of Group I are in late stages of union, whereas those of Group II demonstrate early stages of union throughout the late teens and early twenties. For purposes of easier comparison, our findings may be summarized as follows:

Joint	Age of complete union
Group I	
Ankle	20
Hip	20
Elbow	20
Group II	
Knee	23
Wrist	23
Shoulder	24

It will be noted that the general trend is for our ages of union to be slightly later than those shown in Table 19. As we pointed out in Para. 2, the concept of when union occurs is not universally constant. Thus, on the basis of varying definitions of union, differing results are to be expected. In this regard, Stevenson claims that the epiphysis at the distal extremity of the radius unites at age 19, yet his graph (p. 63) shows cases of non-union for the distal radius in the 21-year age group. Our figures show that complete union occurs in only 40 percent of cases at 19 years and that 100 percent of completed union is not reached until 23 years. Flecker (1942, p. 155) agrees with Stevenson's age of union, but his sample includes cases of non-union as late as 23 years (p. 121). In other words, whereas our ages refer to the age at which all cases are united, the above authors have selected from their frequencies of occurrence some kind of average age. We feel that as a practical tool for age identification, ages other than the end age of union can be misleading and hence our emphasis on the total range of occurrence.

CHAPTER IV

THE INNOMINATE BONE

1. Introduction

The innominate or hip bone, when mature, is one of a pair of large irregularly shaped bones which, with the sacrum, make up the pelvis. Before maturity, each innominate is seen to be composed of three main parts (ilium, ischium and pubis) and several epiphyses. At 17 years of age, the three main elements of the innominate are almost completely united and three epiphyses are ununited: iliac crest, ischial tuberosity and ramus. Also, the symphyseal face of the pubis is undergoing metamorphosis.

In this chapter we shall follow the maturation of these three epiphyses and in addition, since the union of the epiphysis at the symphyseal end of the pubis is only a phase of the metamorphosis of the surface, we shall follow symphyseal changes as a whole throughout our series.

2. Historical Remarks

Morphological changes in the innominate bone and their relationship in general to skeletal age have long been recognized. Hunter in 1761, Aeby in 1858, Henle in 1872 and Cleland in 1889, to cite only a few authors, described gross changes in the hip bone taking place during the life of an individual (see Todd's historical summary, 1920, p. 292). Although most of these authors concentrated their attention upon the pubic symphysis, neglecting the epiphyseal areas of the rest of the bone, they failed to relate specific bone changes to age.

The final step was made when Todd (1920) developed a system of symphyseal phases and Stevenson (1924) made a general survey of epiphyseal union. Both studies could be applied to problems of age identification and are still generally considered as the main authorities. For this reason, a brief review of the methods used in and the conclusions resulting from these studies is in order.

Todd's observations on the documented skeletons at Western Reserve U. showed that the symphyseal face of the pubic bone undergoes a regular metamorphosis from puberty onward. In order to represent

this transformation he identified a succession of 10 phases involving such bony features as a ridge and furrow pattern, a dorsal margin, a ventral bevel, a ventral rampart, lower and upper extremities, and a rim.

To illustrate each of these phases he selected typical specimens of known age (Fig. 23). The phases, as thus typified, he described as follows (Todd, 1920, p. 313):

Phase 1: Age 18-19. Typical adolescent ridge and furrow formation with no sign of margins and no ventral beveling.

Phase 2: Age 20-21. Foreshadowing of ventral beveling with slight indication of dorsal margin.

Phase 3: Age 22-24. Progressive obliteration of ridge and furrow system with increasing definition of dorsal margin and commencement of ventral rarefaction (beveling).

Phase 4: Age 25-26. Completion of definite dorsal margin, rapid increase of ventral rarefaction and commencing delimitation of lower extremity.

Phase 5: Age 27-30. Commencing formation of upper extremity with increasing definition of lower extremity and possible sporadic attempts at formation of ventral rampart.

Phase 6: Age 30-35. Development and practical completion of ventral rampart with increasing definition of extremities.

Phase 7: Age 35-39. Changes in symphyseal face and ventral aspect of pubis consequent upon diminishing activity, accompanied by bony outgrowths into pelvic attachments of tendons and ligaments.

Phase 8: Age 39-44. Smoothness and inactivity of symphyseal face and ventral aspect of pubis. Oval outline and extremities clearly defined but no "rim" formation or lipping.

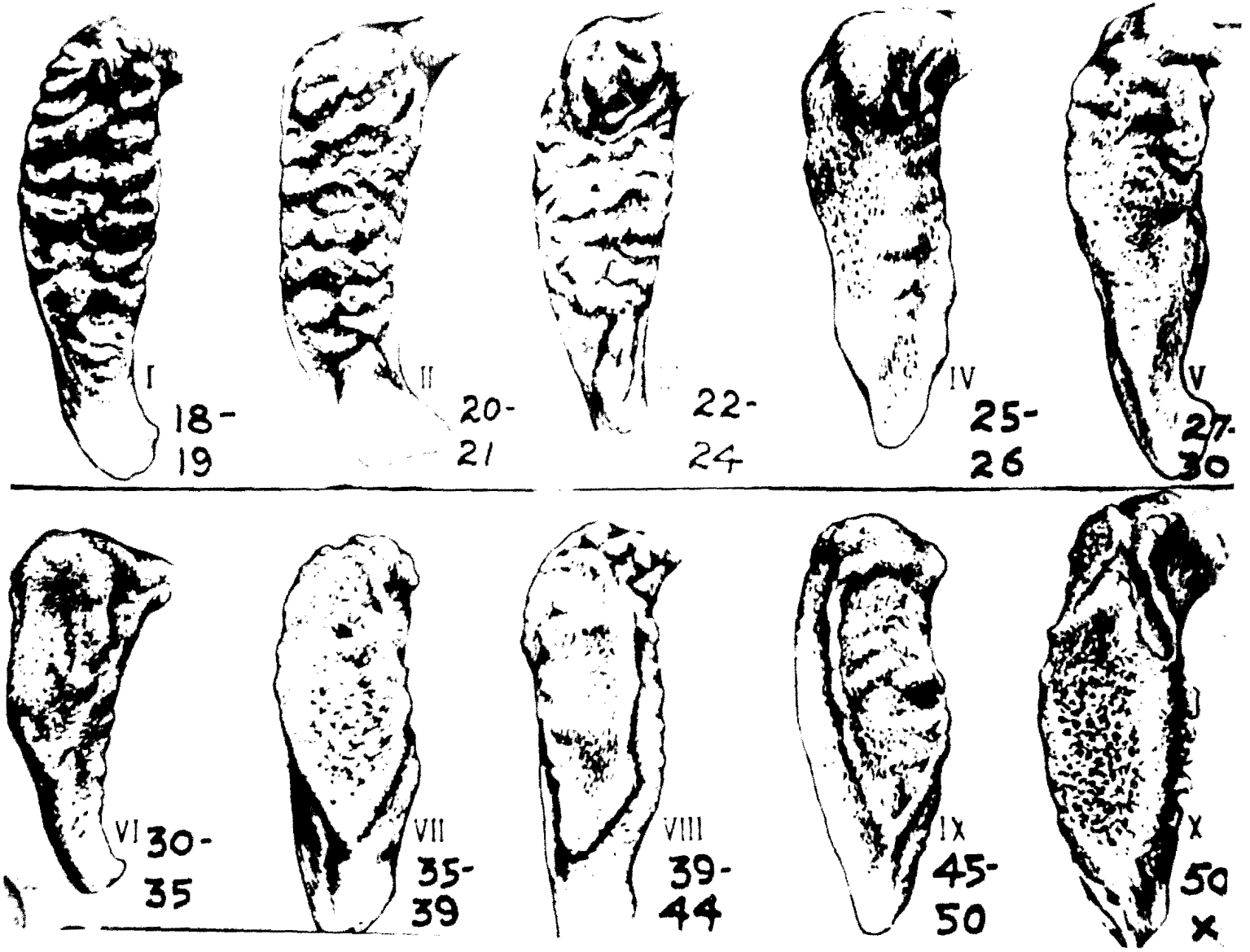

Fig. 23 Modal standards of Todd's 10 typical phases (after G. Neumann).

Phase 9: Age 45-50. Development of "rim" on symphyseal face with lipping of dorsal and ventral margins.

Phase 10: Age 50 and upwards. Erosion of and erratic, possibly pathological, osteophytic growth on symphyseal face with breaking down of ventral margins.

Todd's pubic phases have proved fairly satisfactory for ageing purposes. Recently, however, Brooks (1955) has tested them on a series of 194 male and 177 female California Indian skeletons and a sample of 103 males and 82 females from the Western Reserve collection (the same utilized by Todd). She concludes that for all ages over 20 years the phases consistantly yield a higher than actual age and hence should be modified. Also, she claims that Todd's "extreme deviants" are not necessarily anomalous, but are probably alternative patterns of morphological age changes occurring in the symphyseal surface of the pubis.

It is noteworthy that Todd's pubic phases have also been applied to studies of age changes in the male Japanese pubic bone. Hanihara (1952) investigated a series of 135 male cadavers ranging in ages from 17 to 504. Although his description of symphyseal metamorphosis follows closely that used by Todd, his emphasis of certain features demonstrates a slightly different interpretation. For example, in the age group 36-39, Hanihara gives a detailed description of the bony outgrowth or swelling on the ventral surface of the pubis just adjacent to the ventral rampart (included by Todd in his account of late marginal projections) and refers to it as one of the primary features of late metamorphosis (p. 250). In our analysis of the present series, we were inclined to agree with Hanihara but because of the paucity of our samples in the age groups over 30 years, the importance of this feature was difficult to interpret. Thus, we have included this feature in the general picture of erratic ossification that is exhibited in the symphysis of older individuals (see par. 7).

Hanihara concludes that, "...the changes (referring to the 10 phases) stated by Todd can be used also on Japanese individuals. However, it (symphyseal changes of Japanese pubic bone) does not always coincide with that of Todd in the division of each age period..." (p. 255). He goes on to state (p. 255) that, "...the age changes of the Japanese people are, generally speaking, 2 to 3 years earlier." He is unable to say whether these differences are due to racial variation or to the differences of opinion on the parts of the examiners. The important point, however, is that Hanihara, like Brooks, finds Todd's phases tending to overage many specimens.

We turn now to Stevenson (1924) and his study of epiphyseal union in general. His series consisted of approximately 110 White and American Negro skeletons of both sexes, and ages ranging from 15 to 28 years, the same material studied by Todd. Among the results of his analysis was a detailed description of the sequence of union for the epiphyses of the iliac crest, ischial tuberosity and ramus.

Criticisms of Stevenson's study have been directed primarily to his sample rather than to his methods. For example, Cobb (1952) points out (p. 799) that the death certificate ages of the majority of the collection are not accurate chronological ages and that actually, these ages "represent both antemortem subjective estimate(s) as well as, in lesser degree, postmortem objective guess(es)". Also, Stevenson's breakdown of age, sex and stock (p. 57) shows the obvious limitations created when 110 cases (each segregated according to age, sex and stock) are spread over an age range of 14 years. That is, the highest total for any one group is 9 cases and most are represented by less than 5 cases.

Such criticisms suggest that there is still something to be learned in this area about growth and especially as observed in the sample of young men represented in the American war dead series.

3. Primary Elements

The terminal stage of union between the primary elements of the innominate was observed in only two cases in the 17 year age group and in none of the 18 year age group. This stage consisted of fissures occurring at two sites: 1) the posterior superior angle of the obturator foramen (marking the line of union between the ischium and the pubis) and 2) in the sciatic notch (marking the line of union between the ilium and the ischium, Fig. 24). The significance of this finding is that 17 years represents the final age for union of the primary elements of the innominate.

4. Iliac Crest

The epiphysis for the iliac crest is a long slender piece of bone extending from the anterior superior iliac spine to the posterior superior iliac spine. The epiphysis, when first seen in this series (age 17), is either unattached or in the early stages of fusion and, according to Stevenson (1924, p. 79), should unite in the 22nd year. As usual, we are primarily concerned with variation and thus, with the data collected in the American war dead series, we have attempted to define more accurately the total progress of ossification for the crest.

Observations on the degree of union were recorded on a numerical scale of 0-4 (already described). In addition, the site or sites at which union takes place was recorded in photographs and notes. The

Fig. 24 Left innominate showing stage 4 of union for primary elements. (No. 425, 17 years). Note fissure in the sciatic notch marking the line of union between the ilium and the ischium.

relationship between sites and stages of union can be summarized as follows:

Stage 1. Union begins internally near the anterior superior spine. (Fig. 25)

Fig. 25 Right ilium (external surface) showing stage 1 of union for the iliac crest. (No. 319, 19 years). Note beginning union at anterior superior spine.

Stage 2.

Internally: Fused in anterior half and occasionally at the posterior end. (Fig. 26,top)

Externally: Fused at anterior superior spine and in the middle third. (Sometimes also at posterior end, both internally and externally.) (Fig. 26, bottom)

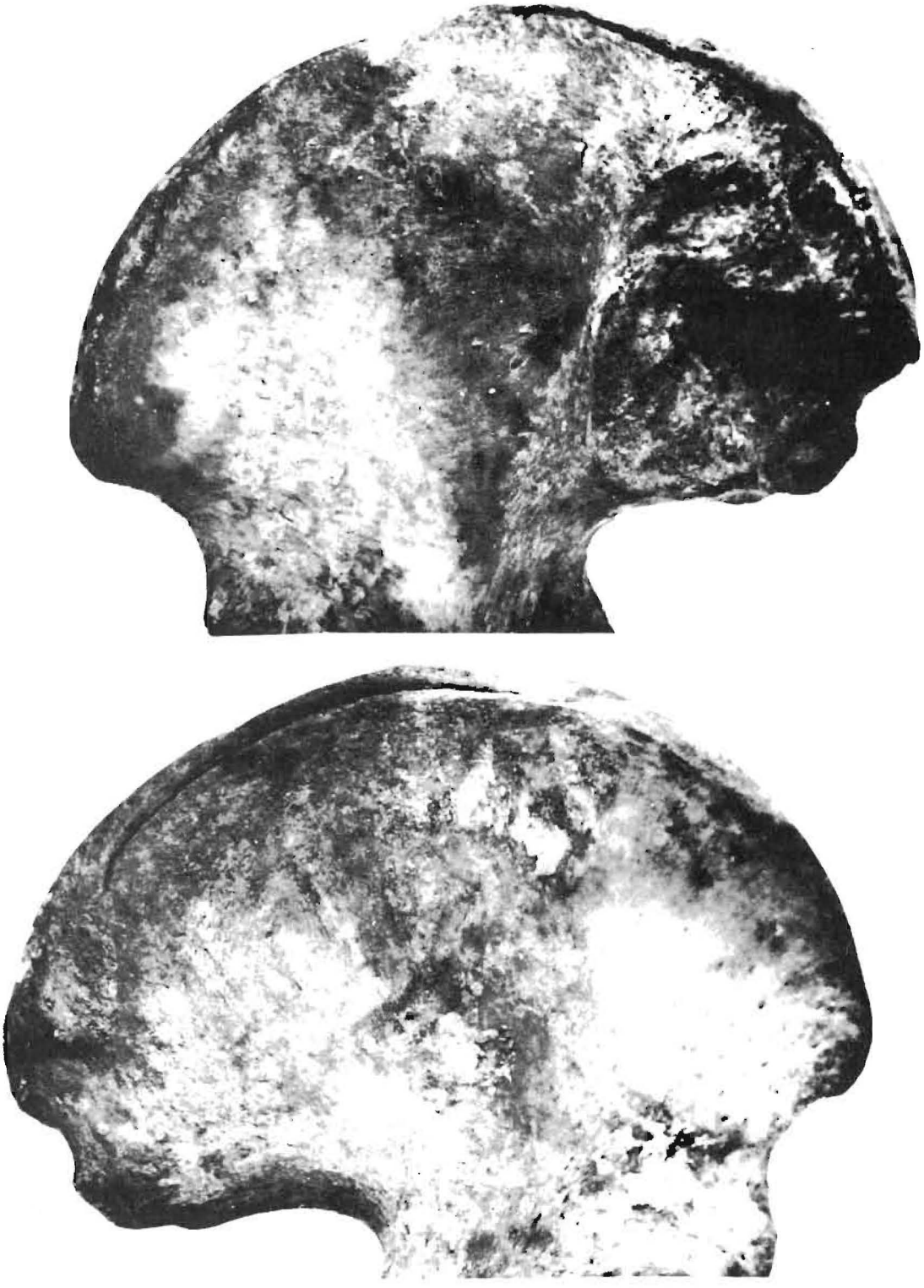

Fig. 26 Top: right ilium (internal surface) showing stage 2 of union for the iliac crest. Bottom: right ilium (external surface) showing stage 2 of union for iliac crest. (No. 348, 19 years.)

Stage 3.

Internally : Ununited only at a point just above the junction of the iliac fossa and articular area. (Fig. 27, top)

Externally: Ununited only at point of greatest anterior thickness. (Fig. 27, Bottom)

Stage 4. Completed union. (The fissures of stage 3 often persist as shallow grooves) (Fig. 28)

Table 22 correlates the above stages with age. From this it is obvious that we are dealing with an epiphysis which in a good many cases has started to unite prior to 17 years; indeed, the majority of crests show some union in both the 17 and 18 year age groups. At the same time, ununited crests appear as late as 20 years while others exhibiting only beginning union appear among the 21 year group. However, in spite of this irregularity, the general picture is one of fairly rapid progress with a period of greatest activity between 20 and 21 years. The crest is completely united at the age of 23 years.

TABLE 22

EPIPHYSIS ON ILIAC CREST: AGE DISTRIBUTION OF STAGES OF UNION (in %)

		Stages of Union				
Age	No.	0	1	2	3	4
17	10	40	10	10	40	-
18	45	18	16	26	20	20
19	52	5	4	27	28	36
20	45	2	6	4	24	64
21	37	-	5	8	13	74
22	24	-	-	4	4	92
23	26	-	-	-	-	100
Total	239					

Following epiphyseal union, lipping soon begins to appear on the inside of the crest just anterior to the junction of the iliac fossa and the articular area (Fig. 29), which is also one of the last sites of epiphyseal union. Lipping appears externally at the point of greatest anterior thickness (Fig. 30), but its occurrence is too erratic to warrant giving an analysis of the data. Table 23 shows the percentage of cases

Fig. 27 Top: left ilium (internal surface) showing stage 3 of union for the iliac crest. Bottom: left ilium (external surface) showing stage 3 of union for iliac crest. (No. 381, 17 years.)

Fig. 28 Top: right ilium (internal surface) showing stage 4 of union for the iliac crest. Bottom: left ilium (external surface) showing stage 4 of union for iliac crest. (No. 324, 19 years).

TABLE 23

ILIAC CREST: LIPPING ON INSIDE AT JUNCTION OF FOSSA AND ARTICULAR AREA.

Age	No.	Percent of Occurrence
22	24	-
23	26	8
24-25	27	30
26-27	25	30
28-30	29	43
31-35	21	72
36-40	15	64
41-50	6	50
Total	173	

Fig. 29 Left ilium (internal surface) showing area of lipping for iliac crest. (No. 445, 28 years).

Fig. 30 Left ilium (external surface) showing area of lipping for iliac crest. (No. 445, 28 years).

in each age group observed to have lipping on the internal side of the crest. It is interesting to note that lipping does not occur before the age of 23 years, but from that age its frequency rises steadily through the upper age groups. We have no explanation for the peak in the age group 31-35 unless it is due to the small number of samples representing the ages over 35.

5. Ischial Tuberosity and Ramus

The epiphysis for the ischial ramus is a ventral extension of that which helps make up the ischial tuberosity. The length of the ramal portion is variable; it may be almost nonexistent (ending at the level of the bottom of the obturator foramen, Fig. 31), or long (in some cases extending onto the inferior extremity of the pubic symphysis, Fig. 32). In this last instance the appearance may be misleading. It is unlikely that an ischial epiphysis extended onto the pubis. Probably at an earlier stage of development, a separate ossification center existed for an epiphysis of the descending pubic ramus, and this became conjoined with the epiphysis of the ascending ischial ramus.

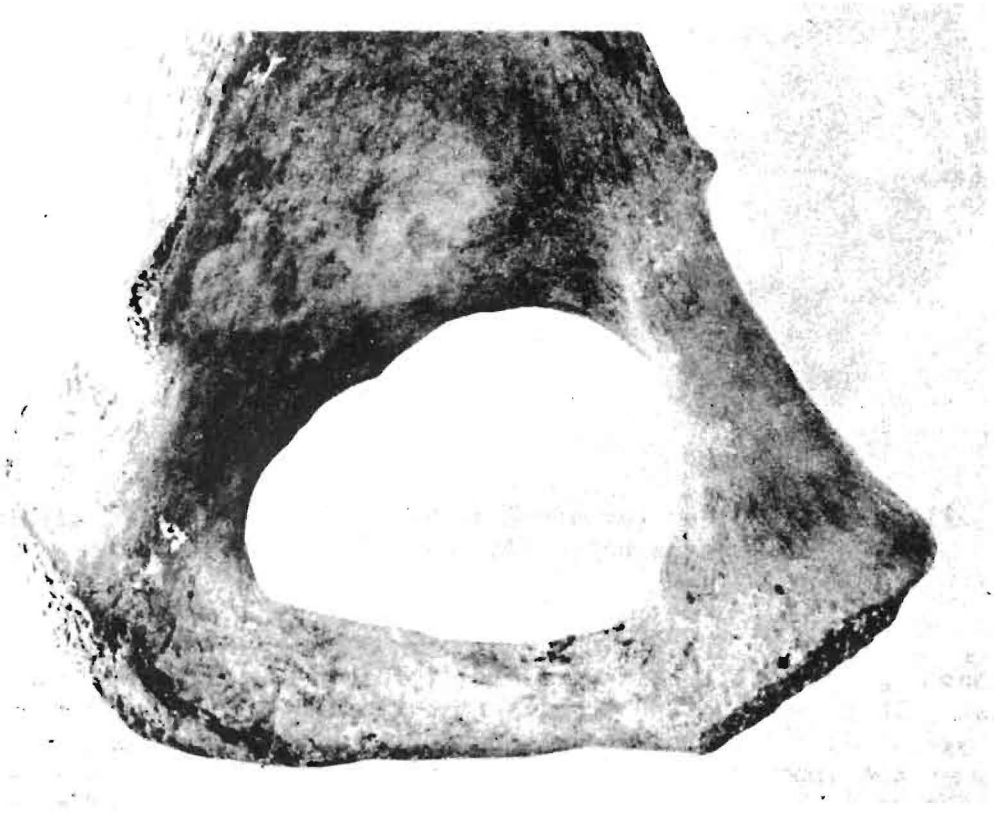

Fig. 31 Left ischium and pubis (internal surface) showing short ramal epiphysis. (No. 118, 32 years).

Regardless of length, this epiphysis follows a pattern of union very much like, but a little more delayed than, that of the iliac crest and, as he did with the crest, Stevenson (1924, p. 79) places complete union at 22 years.

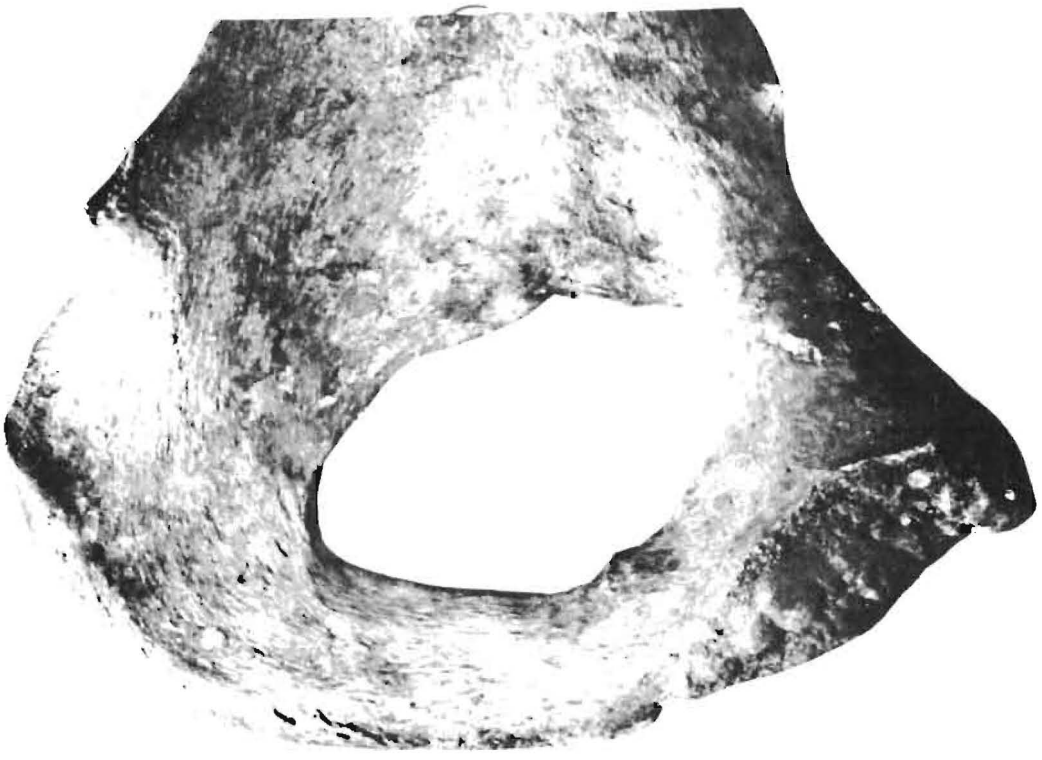

Fig. 32 Left ischium and pubis (internal surface) showing long ramal epiphysis. (No. 82, 20 years)

Our records show that union starts at the posterior end of the tuberosity (Fig. 33) and spreads first along the internal side and then along the external side. After the tuberosity is completely united, the ramal portion is often still unattached. After union of the latter portion, fissures persist for a while (both internally and externally) at the junction of the ramus and tuberosity as well as superiorly on the external side of the ramus. Also, the superior tip of the ramal portion may remain free after the rest has fully fused (Fig. 34).

From Table 24 the progress of union is found to be fairly rapid. Compared to the iliac crest, progress seems to be somewhat more irregular and the final age for complete union is not as distinct. However, after the first half of the 23rd year the ischial epiphysis is completely united in all cases.

Fig. 33 Left ischium showing beginning union of the epiphysis of the tuberosity. (No. 319, 19 years).

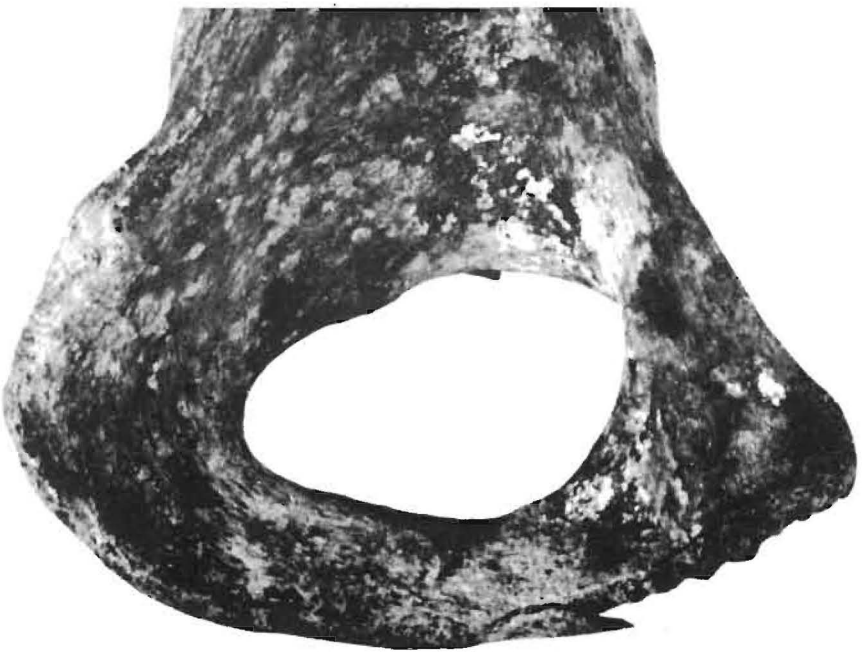

Fig. 34 Left ischium and pubis showing free tip of fully fused ramal epiphysis. (No. 198, 19 years).

TABLE 24

EPIPHYSIS ON ISCHIUM: AGE DISTRIBUTION
OF STAGES OF UNION
(in %)

		Stages of Union				
Age	No.	0	1	2	3	4
17	10	50	10	20	10	10
18	45	52	13	12	12	11
19	52	14	24	13	17	32
20	45	11	13	9	23	44
21	37	10	6	3	25	56
22	24	4	-	-	4	92
23	26	-	-	4	4	92
24-25	27	-	-	-	-	100
Total	266					

At this stage of maturation of the ischium the inner side of the tuberosity presents a ridge along the line where the epiphysis united. This ridge varies somewhat in prominence but is usually smooth and rounded. After some years the ridge becomes more prominent and roughened. This being the case, it was deemed important to learn whether the change in form of this ridge is a useful ageing criterion. The observation was recorded solely from the photographs.

In Fig. 35, 3 specimens are shown representing early, middle and late stages of lipping for the tuberosity. At age 18 (top specimen), the tuberosity is smooth and rounded. Actually, although lipping is not present, the shadowy outline of a slight ridge along the old epiphyseal line can be distinguished. Also, attention is called to the smooth uninterrupted outline of the obturator foramen. At age 26 (middle specimen), the tuberosity is definitely lipped

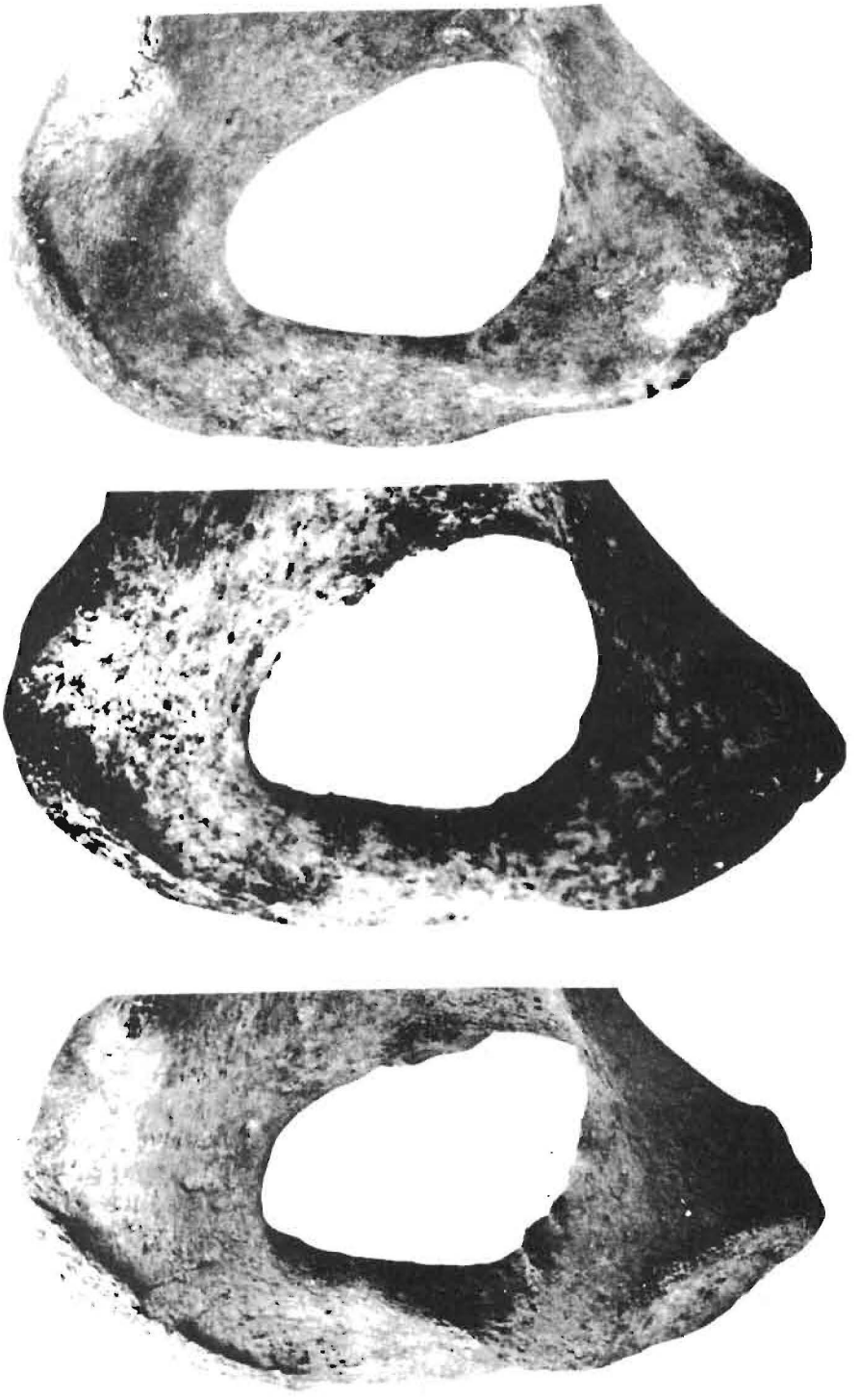

Fig. 35 Left ischia showing (top) early, (middle) middle, and (bottom) late stages of lipping for the tuberosity. (No. 284, 18 years; No. 112, 26 years; No. 444, 36 years).

and its border is no longer smooth but has become slightly serrated. Also, the smooth outline of the obturator foramen is now interrupted by small bony nodules (usually found near the anterior and posterior obturator tubercles). At age 36 (bottom specimen), lipping and serration is more pronounced. Here the changes are not confined to the tuberosity, as in the 26 year old specimen but extend along the ischial ramus. The exostoses around the borders of the obturator foramen are also more pronounced (demonstrated also in Fig. 36).

Fig. 36 Right ischium and pubis showing exostoses around the border of the obturator foramen. (No. 379, 32 years).

In general, the formation of lipping and exostoses about the ischium appears to be a gradual and erratic process and such changes tend to become pronounced in the latter part of the fourth decade. However, it should be apparent that they are not accurate age indicators.

6. <u>The Pubic Symphysis: A new system for determining age</u>.

The symphyseal face of the pubis is a nearly ideal area in which to seek evidence on skeletal maturation. Not only are there a succession of changes taking place, but these changes extend into the later decades of adult life, a period for which evidence from other parts of the skeleton is mostly lacking.

Todd may have been essentially right in his selection of cases to typify successive age periods, but the result was a static method of age determination. Since the variability of each feature was lost, only those pubic bones which are close to the typical can be aged with reasonable accuracy.

We feel that the main contribution we can make to this subject is an analysis of our data which takes into account all variations. In order to accomplish this, an approach somewhat different from Todd's is required. Rather than divide the whole course of symphyseal metamorphosis simply into 10 phases, we will make it possible to translate a large number of morphological combinations into chronological terms. Separate components of each symphyseal face can be recognized, and also the fact that each of these undergo transformation by stages. The result may be expressed as a formula, and a review of all formulae by age will provide a basis for judging the position of a particular case relative to the mode.

The idea of summarizing complex morphology by means of a formula is not new to biological science. A well known example is the somatotype formula introduced by Sheldon (1940). In this case a formula, consisting of 3 components of 7 grades each, described the body type of an individual. Such a procedure not only forces the observer to analyze the composition of a structure but, once formulated, enables anyone to visualize what the original structure looked like. Moreover, a formula is a convenient device for comparative purposes.

To serve description most efficiently, a formula must have certain limitations. If composed of too many elements, the significance of each element becomes difficult to remember; on the other hand, if reduced to too few elements, the discriminating function becomes lost. After some experimentation with elements involved in metamorphosis of the symphysis, we felt that the best results were obtained from a formula consisting of 3 components with 5 subdivisions or grades each.

Our search for the main elements began, naturally, with Todd's description of the changes in the pubic symphysis. In the course of this description he introduced 9 "features" in the following order:

1. Ridges and furrows
2. Dorsal margin
3. Ventral beveling
4. Lower extremity
5. Superior ossific nodule
6. Upper extremity
7. Ventral rampart
8. Dorsal plateau
9. Symphyseal rim

Obviously, a formula of 9 digits, which would result if all 9 features were used, would be cumbersome. Therefore, we were faced with the problem of dealing with combinations of previously described features.

At age 17, the starting point of our series, the most prominent feature of the symphyseal face is a pattern of transverse ridges and furrows (Todd's feature 1). The pattern is often interrupted by a semblance of either a longitudinal ridge or groove, bisecting part or all of the symphyseal face and dividing it into dorsal and ventral halves (Fig. 37). We feel that this division is important because it foreshadows events that will be restricted to one or the other side. For convenience in referring to this division, we are using the expressions, "dorsal demi-face" and "ventral demi-face."

Fig. 37 Symphyseal face of the pubis showing the left longitudinal ridge and right longitudinal groove which divides the face into dorsal and ventral halves (dorsal is left and ventral is right). (No. 88, 18 years; No. 139, 18 years).

Since ridge and furrow obliteration is retrogressive in character, gradually disappearing into other features, it seems best to consider it not as a separate feature but as a part of succeeding features.

Next, our analysis of the present series convinced us that the lower symphyseal extremity (Todd's feature 4) occurs in combination with the expansion inferiorly of the dorsal margin, that the upper extremity (Todd's feature 6) is closely associated with the development of the ventral border, and that the so-called ossific nodule (Todd's feature 5) which is found in only a small number of cases and quickly loses its

identity, is but the upper part of the ventral rampart. These considerations again led us to believe that such features can be included in the descriptions of the two demi-faces.

Lastly, we combined Todd's features 2 and 8 (dorsal margin and plateau) and features 3 and 7 (ventral beveling and rampart). In further recognition of the essential division of the demi-faces, we feel that the functional relationship of dorsal margin to dorsal plateau, and ventral beveling to ventral rampart are extremely close and thus can be considered as interrelated features. This leaves only one of Todd's features (No. 9 or the symphyseal rim) distinct from the demi-faces. Actually it involves the face as a whole and only after the original subdivision has disappeared. In this way, we have arrived at 3 components that we consider diagnostically reliable in their chronologic behavior: 1) the dorsal plateau, 2) the ventral rampart and 3) the symphyseal rim.

The components do not represent a succession of structural changes which are clearly distinguishable by inspection; instead, they develop gradually and often must be subdivided quantitatively on the basis of experience. After all, the system depends entirely upon what the eye sees and the relationship of the observations with age must be worked out on this basis.

As one would expect, metamorphosis is not always in the same direction. A structure such as the dorsal plateau develops gradually, becomes complete, and then proceeds to break down and disappear. On the other hand, the symphyseal rim, having reached its peak in the mid-thirties, thereafter gradually disintegrates and eventually is replaced. Unavoidably, the numbers used in designating the stages, and hence the formula, ignore the changes in direction. Having the numerical sequence of the stages parallel the direction of the structural changes would only complicate the visual usefulness of the formula. Therefore, since the aim of this analysis is to develop a practical formula for estimating age, we have numbered the active stages of all components from 1 to 5.

In addition to the 5 active developmental stages, a preliminary stage (0), denoting absence of the feature in question, precedes each set of stages. We will now define the 3 components and their developmental stages.

7. <u>The Symphyseal Components</u>

I. <u>Dorsal Plateau</u>. Between the ages of 17-18, the grooves near the dorsal margin begin to fill in with finely textured bone and the ridges show the first evidence of resorption. Coincident with this process, a delimiting dorsal margin appears which eventually outlines

the entire demi-face.

Starting in the same general area, the interacting processes of resorption and fill-in spread over the dorsal demi-face until the ridge and groove pattern has been obliterated. Ultimately, this gives to the demi-face a flat, platform-like aspect and for this reason, the component has been given the name, dorsal plateau.

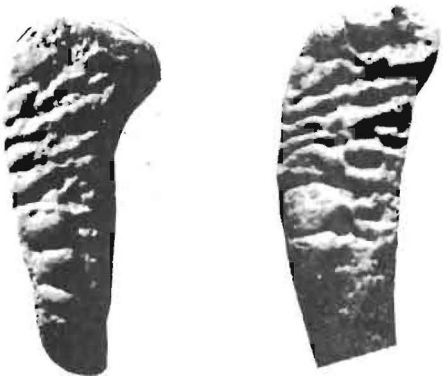

Fig. 38 Symphyseal face of the pubis showing the dorsal nodules on the inferior dorsal demi-face. (No. 188, 18 years; No. 139, 18 years)

Attention is called to the dorsal nodules (not described by Todd), sometimes associated with the early metamorphosis of the dorsal demi-face (Fig. 38). When present, they are found in the lower third of the demi-face. They are not simply enlarged ridges but round lumps of bone incorporated in the ridges. Since they do not aid in delimiting the lower symphyseal extremity and appear in only a small number of cases, we have not regarded them as a distinctive part of Component I.

The 6 (0-5) stages of Component I follow: (Fig. 39)

0. Dorsal margin absent.
1. A slight margin formation first appears in the middle third of the dorsal border.
2. The dorsal margin extends along entire dorsal border.
3. Filling in of grooves and resorption of ridges to form a beginning plateau in the middle third of the dorsal demi-face.

COMPONENT I

I-1 I-2 I-3 I-4 I-5

Fig. 39 The 5 active stages of Component I.

4. The plateau, still exhibiting vestiges of billowing, extends over most of the dorsal demi-face.
5. Billowing disappears completely and the surface of the entire demi-face becomes flat and slightly granulated in texture.

II. Ventral rampart. Early in the development of Component I, differentiation of dorsal and ventral demi-faces becomes pronounced due to the breakdown, by rarefaction, of the ventral half. Over this porous, beveled surface, an elongated and more or less complete epiphysis or rampart forms. This rampart is produced by the extension of ossification from upper and lower extremities aided, at times, by independent ossicles along the line of the future ventral margin. Obviously, however, the pattern is variable and the rampart may remain incomplete even in later age groups (the hiatus is usually in the middle two-thirds of the ventral border, Fig. 40) or may bridge only certain portions of the beveled surface.

Fig. 40 Symphyseal face of pubis showing ventral hiatus. (No. 239, 29 years).

The 6 (0-5) stages of Component II are as follows: (Fig. 41)

0. Ventral beveling is absent.
1. Ventral beveling is present only at superior extremity of ventral border.
2. Bevel extends inferiorly along ventral border.
3. The ventral rampart begins by means of bony extensions from either or both of the extremities.
4. The rampart is extensive but gaps are still evident along the earlier ventral border, most evident in the upper two-thirds.
5. The rampart is complete.

COMPONENT II

II-1 II-2 II-3 II-4 II-5

Fig. 41 The 5 active stages of Component II.

III. Symphyseal rim. The final stages of symphyseal maturation are characterized by the formation of a distinct and elevated rim surrounding the now level face. At the same time, the bony texture of the face begins to change from a somewhat granular to a more finely grained or dense bone and, although vestiges of the ridge and groove pattern still may be recognized in the lower third of the dorsal demi-face, it is sometimes difficult to tell whether they are merely regular undulations of the smooth bony surface or true remnants of the earlier ridge and groove pattern.

Following the completion of the symphyseal rim, there is a period during which changes are minute and infrequent. Ultimately the rim is worn down or resorbed and a smooth surface extends to the margins. As the face levels off it undergoes erosion and erratic ossification, the bone becomes more porous and the margins may be lipped.

Metamorphosis of the symphysis in the last decades of life is characterized by further breakdown of the bony tissue. However, because of the small number of older individuals present, the series under discussion does not enable us to define the last stages clearly.

The 6 (0-5) stages of Component III are as follows: (Fig. 42)

0. The symphyseal rim is absent.
1. A partial dorsal rim is present, usually at the superior end of the dorsal margin, it is round and smooth in texture and elevated above the symphyseal surface.
2. The dorsal rim is complete and the ventral rim is beginning to form. There is no particular beginning site.
3. The symphyseal rim is complete. The enclosed symphyseal surface is finely grained in texture and irregular or undulating in appearance.
4. The rim begins to break down. The face becomes smooth and flat and the rim is no longer round but sharply defined. There is some evidence of lipping on the ventral edge.
5. Further breakdown of the rim (especially along superior ventral edge) and rarefaction of the symphyseal face. There is also disintegration and erratic ossification along the ventral rim.

8. Correlations with Age

After having constructed the symphyseal formula and defined the components' changes, our next step was to see whether others could apply

COMPONENT III



III-1 III-2 III-3 III-4 III-5

Fig. 42 The 5 active stages of Component III.

TABLE 25

THE AGE DISTRIBUTION OF COMPONENT STAGES

		Component I						Component II						Component III					
		Stages						Stages						Stages					
Age*	No.	0	1	2	3	4	5	0	1	2	3	4	5	0	1	2	3	4	5
17	5	5						5						5					
18	23	2	8	11	2			23						23					
19	57		5	35	16	1		51	5	1				57					
20	52		2	16	26	8		34	16	2				52					
21	33		1	4	20	8		8	13	5	7			31	2				
22	21				7	14		1	7	5	5	3		16	5				
23	29				6	20	3		5	4	12	8		15	14				
24	16				1	8	7			1	7	7	1	3	8	2	3		
25	8					3	5				3	3	2		3	3	2		
26	13					9	4				3	10	0		5	7	1		
27	12					7	5				4	5	3		4	3	5		
28	13					6	7				2	7	4		2	7	4		
29-30	15					1	14					11	4			9	4	2	
31-39	45						45					6	39			5	12	26	2
40-50	7						7						7					5	2
Total	349																		

*Represents age to the nearest year, for example, 17 = 16.5 to 17.4

it with similar results. Such a test was especially necessary since the judgment of component stage and age correlation was based on the subjective observations of one investigator (McKern). Before accepting this judgment as final, several observers not in contact with the project were asked to study the instructions and then to work out the formulae of 10 selected casts. The results of this test demonstrated that after a little practice with the method, observers with only a general knowledge of osteology could formulate normal symphyses with about 90% accuracy. After more experience, the same observers improved further in their formulation.

With this evidence that others can judge the components and their stages on the basis of our descriptions, we proceeded to analyze each symphysis into its formula. For example, a symphysis from the beginning of the series would have the simple formula of 1-0-0, indicating that only the first stage of the dorsal plateau component is present. This stage (I-1) would then be scored as occurring at 18 (the known age of the individual). Later in the series, if we encountered the formula 3-3-0 in a symphysis from a 21 year old individual, we could score the stages I-3 and II-3 under his age. Thus, when all the formulae were scored, an age distribution resulted which is shown in Table 25.

According to Table 25, the first and second stages of Components I and II develop fairly rapidly and are completed in 4 to 6 years, whereas the last stages progress more slowly. In Component III the first stage begins late (21 years) and takes 8 years to complete, whereas the 2nd and 3rd stages take from 16 to 21 years. In our series some stages never reached completion, as 5 of Component I, 4 and 5 of Component II, and 3, 4 and 5 of Component III. Small samples in the age groups over 28 years are reflected in the distributions of stages 4 and 5 of Component III. Necessarily therefore, these final stages are only tentatively defined.

Obviously, this is a picture of deceleration in symphyseal metamorphosis. Component III, in particular, represents a period which Todd characterized as one of "quiescence" when age changes were limited to peripheral outgrowths into attachments of tendons and ligaments.

It will be noted also in Table 25 that the modal age is given up to age 28 whereas all ages over 28 years have been combined into 3 age groups and hence here the position of the mode is masked. For this reason it seems desirable to give the mode and range for each stage in a separate table (Table 26).

The formulae now may be translated into probable ages. For example, reading from Table 26 the formula 3-0-0 has an overall range of 18-24 years (the earliest and latest appearance of any stage of the 3 components) and a modal frequency of 20, 19, and 19 years (the designated modes of each component stage) for the 3 components. Thus, a final

judgment of the individual's most probable age at death would be 19+ years.

TABLE 26

AGE LIMITS OF THE COMPONENT STAGES

Stage	Age Range	Mode
	Component I:	
0	17.0 - 18.0	17.0
1	18.0 - 21.0	18.0
2	18.0 - 21.0	19.0
3	18.0 - 24.0	20.0
4	19.0 - 29.0	23.0
5	23.0 +	31.0
	Component II:	
0	17.0 - 22.0	19.0
1	19.0 - 23.0	20.0
2	19.0 - 24.0	22.0
3	21.0 - 28.0	23.0
4	22.0 - 33.0	26.0
5	24.0 +	32.0
	Component III:	
0	17.0 - 24.0	19.0
1	21.0 - 28.0	23.0
2	24.0 - 32.0	27.0
3	24.0 - 39.0	28.0
4	29.0 +	35.0
5	38.0 +	

Although there are 125 possible formula combinations, only about one fourth of these combinations are likely to occur. In the present series, 21 different formulae were recorded, as follows:

000	320	431	543
100	330	441	552
200	410	442	553
210	420	541	554
300	430	542	555
310			

Obviously, since the components represent a chronological developmental process, certain combinations would be impossible or, at least, pathological. However, this is not to say that the above list includes all the normal combinations. Others will likely appear when the system is applied to more extensive series. However, we believe that if other formulae are found, they will yield age estimates that are in accord with those represented in this study.

Also, it is expected that there may be differences of opinion in the recording of various stages of component development. For example, it is often difficult to determine whether the second component is in stage 4 or 5 and similarly, whether the third component is in stage 2 or 3. The resulting formula could be either 542, 543, 552 or 553. However, these difficulties actually reflect the close interrelations of Components 2 and 3 at this particular period of metamorphosis and the mean ages for all four formulae are practically the same. Thus, the system is flexible to the point where slight deviations in observation will not necessarily produce grave errors in age estimations.

Carrying the analysis a step further, we found that when the figures comprising the formula (300 = 3, 431 = 8, etc.) were added together, the resulting values, when plotted against age, showed distributions exhibiting few, if any, differences from those of the intact formulae. Table 27 thus shows the calculated means and their age ranges for each total score (0-15). Since several of the scores gave similar age estimations, these scores have been lumped into a single category. We can then conclude that once a symphyseal formula has been established, the age range and the probable age of the individual at death can be estimated by simply calculating the sum of the 3-digit formula and reading the corresponding age from Table 27.

Attention is called again to the small number of individuals in the upper age groups and to the possibility that they may not give a full picture at the later stages of metamorphosis. Eventually, our observations should be checked on a large sample of older individuals and adjustments made if necessary.

To properly utilize the symphyseal formula, the user must correctly visualize a particular symphysis in terms of the established component stages. Although the stages are described verbally and portrayed photographically, the prime requisite is for realistic and three-dimensional training aids to insure comparability between users and maximum accuracy in assessment. To this end, sets of plastic model symphyseal casts, representing the three components and their 5 developmental stages have been fabricated (Fig. 43). With an enclosed sheet of instructions and in combination with the information contained in the present report

the plastic sets become effective tools for ageing unknown skeletal remains.*

TABLE 27

CALCULATED MEAN AGE, STANDARD DEVIATION AND AGE RANGES FOR THE TOTAL SCORES OF THE SYMPHYSEAL FORMULAE

Total Score	No.	Age Range for the Scores	Mean Age	Standard Deviation
0	7	- 17	17.29	.49
1-2	76	17 - 20	19.04	.79
3	43	18 - 21	19.79	.85
4-5	51	18 - 23	20.84	1.13
6 -7	26	20 - 24	22.42	.99
8-9	36	22 - 28	24.14	1.93
10	19	23 - 28	26.05	1.87
11-12-13	56	23 - 39	29.18	3.33
14	31	29 +	35.84	3.89
15	4	36 +	41.00	6.22
Total	349			

9. Abnormalities of the Symphysis

Abnormalities of the symphysis complicate age identification and hence have pertinence to the present study. They fall into 2 categories: postmortem erosion and antemortem malformation.

In assembling the series under discussion, poorly preserved skeletons and especially those in which the symphyses were badly eroded, were rejected. The small amount of erosion which was accepted obscures rather than distorts symphyseal features. We believe that such obscuration as existed has not seriously reduced the accuracy of formulation for identification purposes.

*Plastic symphyseal model sets are fabricated by:
Darrell Van Buren, Inc.
81 Diamond Street
Walpole, Massachusetts

Fig. 43 The set of plastic model symphyseal casts.

On the other hand, there was no conscious or planned selection against local antemortem malformations. As would be expected, however, such abnormalities are rare in this type of population. In Fig. 44, cases #329 and #250 illustrate two distinct types of deformed symphseal faces.

The type represented by case #329 (23 years old) occurs in 3 out of the total series of 371 pelves. Compared to a normal symphyseal face, it is extremely small and exhibits none of the diagnostic features characteristic of its age. The type represented by case #250 (22 years old) was seen in 4 cases. Here a peculiar disintegration of the upper portion of the face (usually indicative of advanced age) accompanies features in the lower portion of the face characteristic of the true age. The other examples of this type have disintegrated in various places and hence the type is to be identified by the breakdown of the face rather than by the location of the breakdown.

In all of our cases of antemortem malformation of the symphyseal face, the rest of the skeleton shows a normal growth pattern. This

Fig. 44 Symphyseal face of pubis showing types of deformed symphyses. (No. 329, 23 years (above); No. 250, 22 years (below)).

suggests that such malformations may have resulted from trauma to the pubic area. Whatever the cause, it is important to recognize such conditions and to discount them in favor of other more reliable ageing criteria.

10. Summary

Primary elements. Last signs of union for the primary elements of the innominate occur as small fissures at points of union between the ischium, pubis and ilium.

Iliac crest. The early stages of epiphyseal union for the iliac crest are in progress prior to the 17th year. The site of earliest union is at the anterior end of the crest, usually on the medial side and just posterior to the anterior superior iliac spine. The crest is

completely fused by the age of 23 years and the last sites of union are at the junction of the iliac fossa and articular area (medially) and at the point of greatest anterior thickness (laterally).

Ischial tuberosity and ramus. The ischial epiphysis is fully united at 23 years and the last site of union seems to be on the external side of the ramus.

Pubic symphysis. Since Todd's system of typical phases serves only those symphyses that conform to his concept of typical, we have proposed a new method of ageing in which symphyseal metamorphosis is evaluated in terms of combinations of its component parts. Thus, we have selected 3 components, each subdivided into 5 developmental stages which, when combined as a formula for any pubic symphysis, will yield an age range and the probable age of the individual. In comparison to Todd's system, the symphyseal formula expresses the true nature of symphyseal variability and does not confine the observer to the narrow limits of typical phases.

CHAPTER V

CLAVICLE

1. Introduction

The medial end of the clavicle articulates with the sternum, and the lateral end with the acromial process of the scapula. Both articular areas are the sites of small and highly variable epiphyses.

The lateral epiphyseal surface is usually small and billowed in the typical fashion. The epiphysis itself is seldom seen and the surface simply glazes over rapidly, around 19 or 20 years, a time when much epiphyseal activity is going on elsewhere in the skeleton. Since the status of this epiphysis is difficult to judge, no provision was made for it on the data card and only occasionally was a cast made of this end of the bone.

On the other hand, the epiphyseal surface at the medial end is relatively rich in detail and matures at a slow rate. Also, extra importance attaches to this epiphysis because of its late time of maturation; it is the last epiphysis to unite. For these reasons, all cases were rated on the usual scale of 0 to 4 and supplemented by a cast and photograph of both sides, taken together.

2. Historical Remarks

Although the clavicle has long been a subject of study, reliable data on the maturation of its epiphyses were not reported until the 1920's when the Todd skeletal collection was formed. Before that time, anatomical text books contained very little about the maturation of the lateral epiphysis and varying statements, based on data of unknown origin, about that of the medial epiphysis.

Age estimations by various authors for the union of the medial epiphysis follow:

Author	Year	Age
Henle	1872	18
Krause	1909	20-21
Dwight	1911	18
Poirier	1911	25
Dixon	1912	25
Bryce	1915	25
Lewis	1918	25
Terry	1921	25
Testut	1921	22-25
Thompson	1921	25

Stevenson (1924) was the first to study the maturation of the clavicles in the Todd collection. On the basis of 50 specimens between the ages of 21 and 27 he was able to say that,

> "The epiphysis in question shows evidence of beginning union in several of the twenty-two year skeletons, and of having only recently united in several of the twenty-seven year individuals. In fact, it is not until the twenty-eight year old group is reached that this epiphysis is found to be united in all the cases. The usual impression that this epiphysis unites more or less constantly at the twenty-fifth year, and the common practice of considering skeletons to be either older or younger than twenty-five according to whether the sternal epiphysis of the clavicle is united or ununited, seems entirely unwarranted. It is impossible to assign any age at which this epiphysis will certainly be completely united below the twenty-eighth year."

Later Todd and D'Errico (1928) were able to expand the series to 166 specimens (including Stevenson's 50) and the age range to 17 and 29 years. Their charts show that union may begin as early as 20 years (1 case) and may still be in the "recent" stage as late as 29 years (2 cases). Nevertheless, they state (p. 37):

> "In both sexes and both races (White and American Negro) union of the sternal epiphysis is practically completed in the twenty-fifth year (R)."

Note that here "practically complete" union is equated with "recent" union. The authors recognize this equation again when they say (p. 37):

> "The loss of all traces of the site of union (C) quickly follows. Of course there are exceptions, mainly in the four years centering on twenty-five."